Module 5 - MPR et pathologies du système nerveux central et handicap sensoriel

IRM cérébrale en pratique de MPR

Jacques Luauté

One function : many regions

localizationist theory

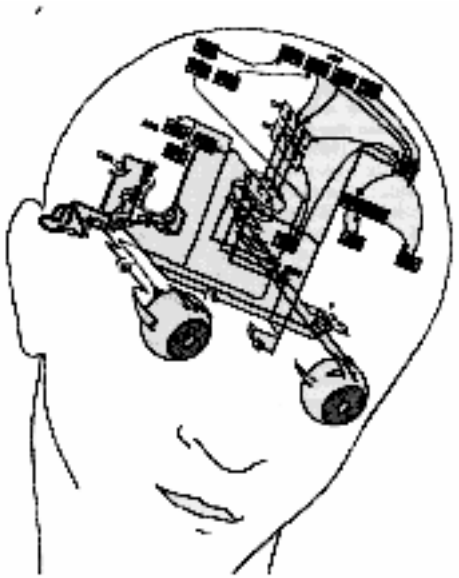

Connectomic approach

One region: many functions (e.g. Broca area)

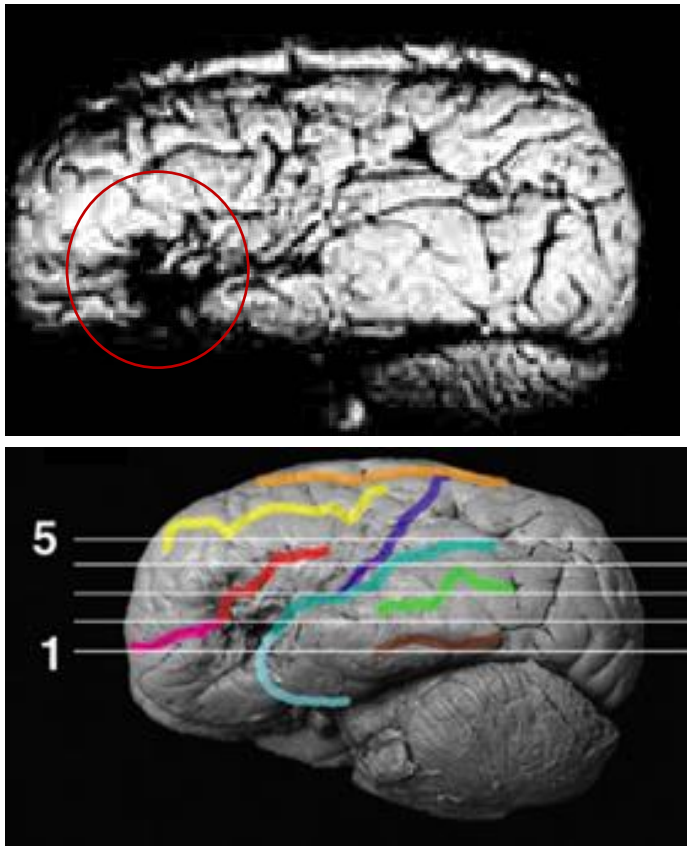

Dronkers et al. Brain 2007

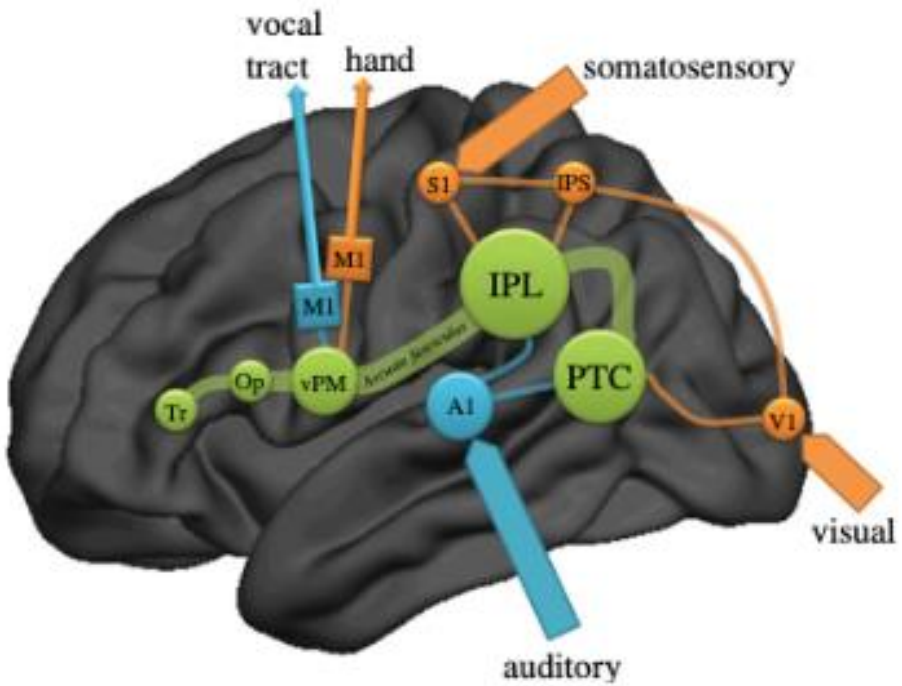

Stout & Chaminade Phil. Trans. R. Soc. B 2012

Brain plasticity

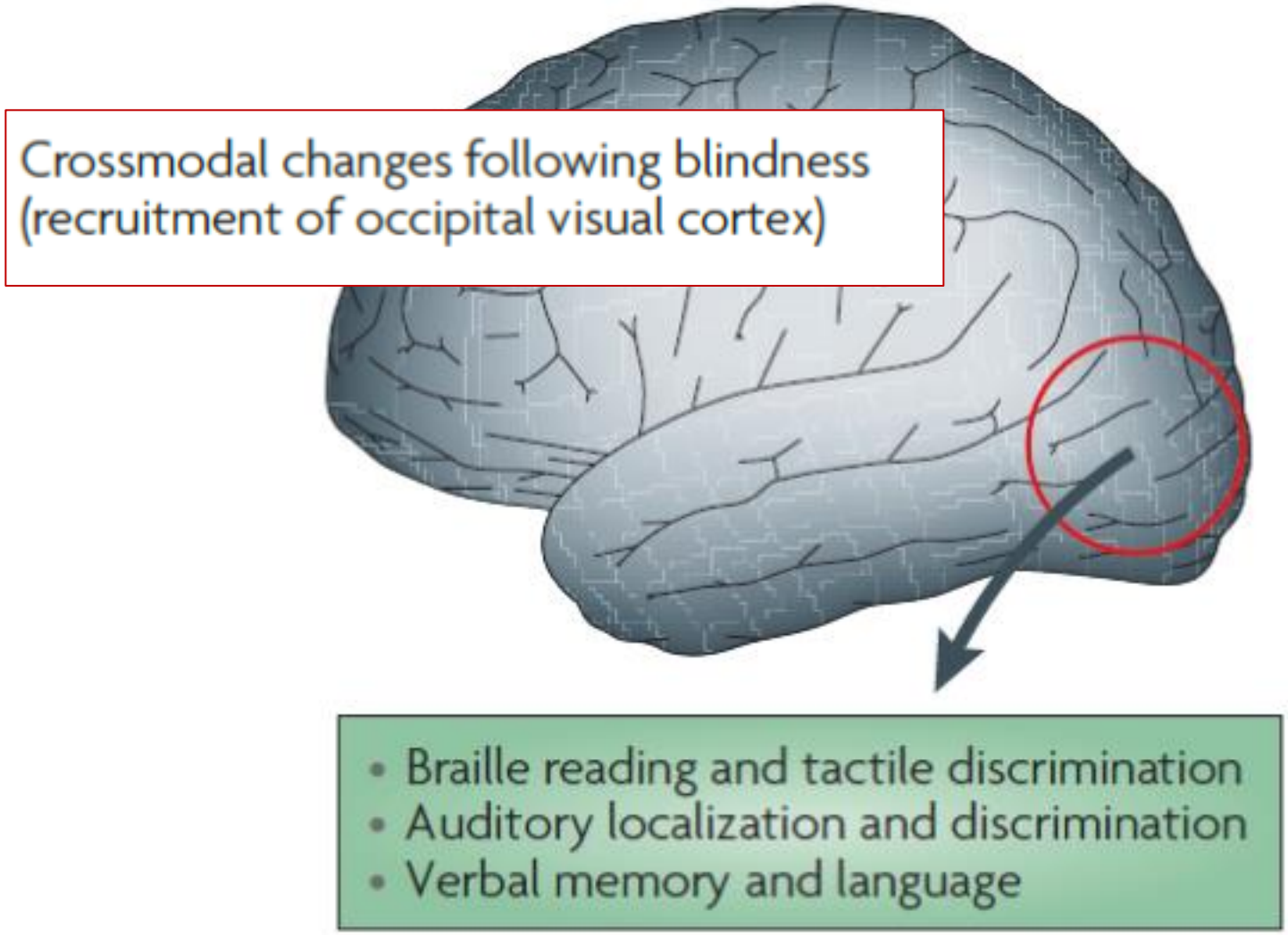

Merabet and Pascual-Leone Nature Reviews Neuro 2010

From a 3D brain to 2D sections

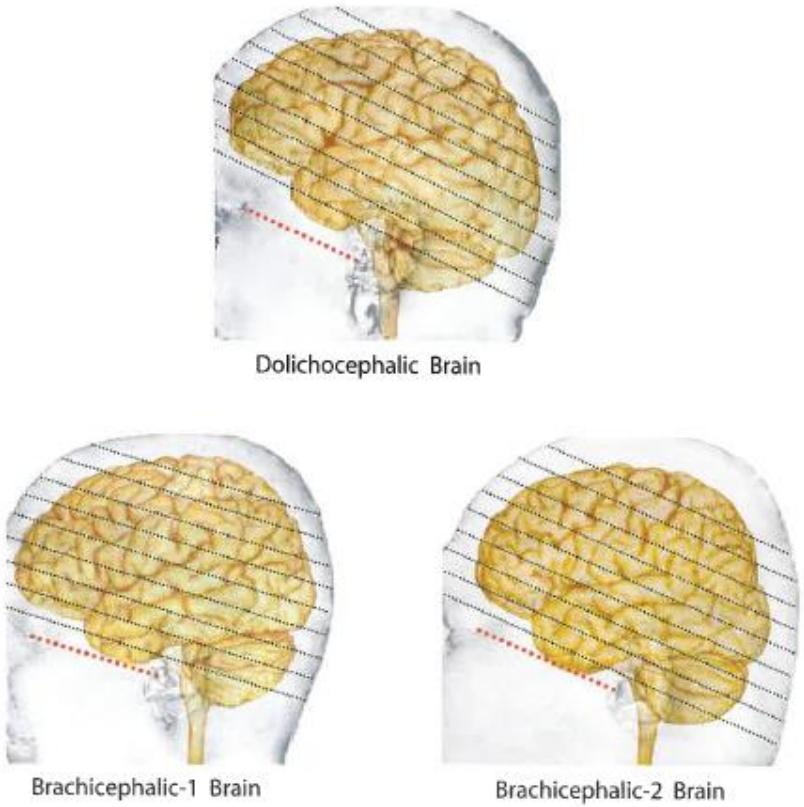

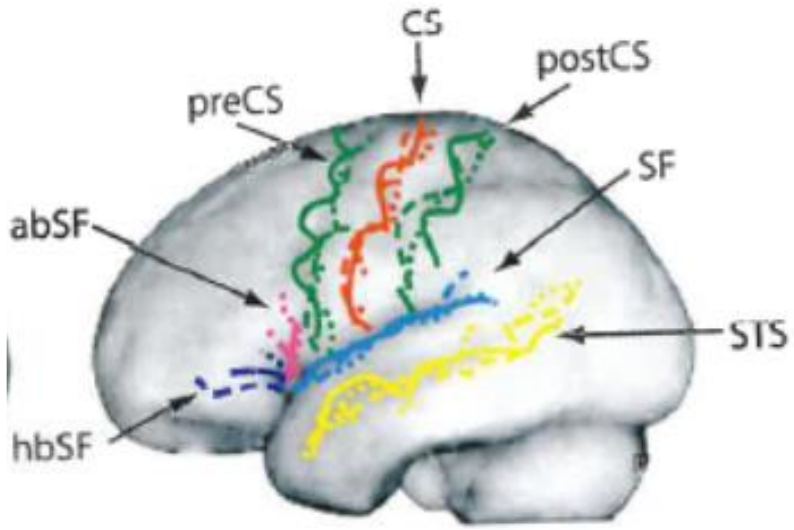

Copied from Human Brain Anatomy in computerized images – Hanna Damasio

How to recognize key regions of the brain

- Recognizing the four lobes
- Motricity: Identifying the primary motor cortex
- Somato-sensory regions :Identifying the primary somatosensory cortex
- Vision :Identifying the primary visual cortex
- Memory : Identifying the hippocampus
- Language: Locate Broca and Wernicke areas
- Visuo-spatial functions : Recognize the superior and inferior parietal lobules

The frontal lobe

- Anatomical location
  - In front of the parietal lobe, separated by **the central sulcus** (Rolando)
  - Above the temporal, separated by **the lateral sulcus** (Sylvius)

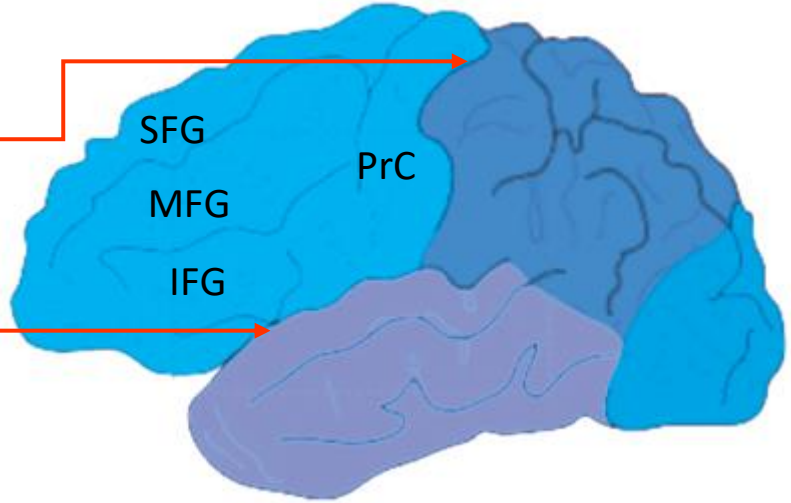

Recognizing the central sulcus

- The central sulcus looks like a hook or a omega Ω at its middle localization.

Recognizing the central sulcus

- Usually posterior central gyrus has less thickness than anterior one.

Recognizing the central sulcus

- Precentral sulcus is anterior to the precentral gyrus and it touches the superior frontal sulcus
- The central sulcus is posterior to the precentral gyrus

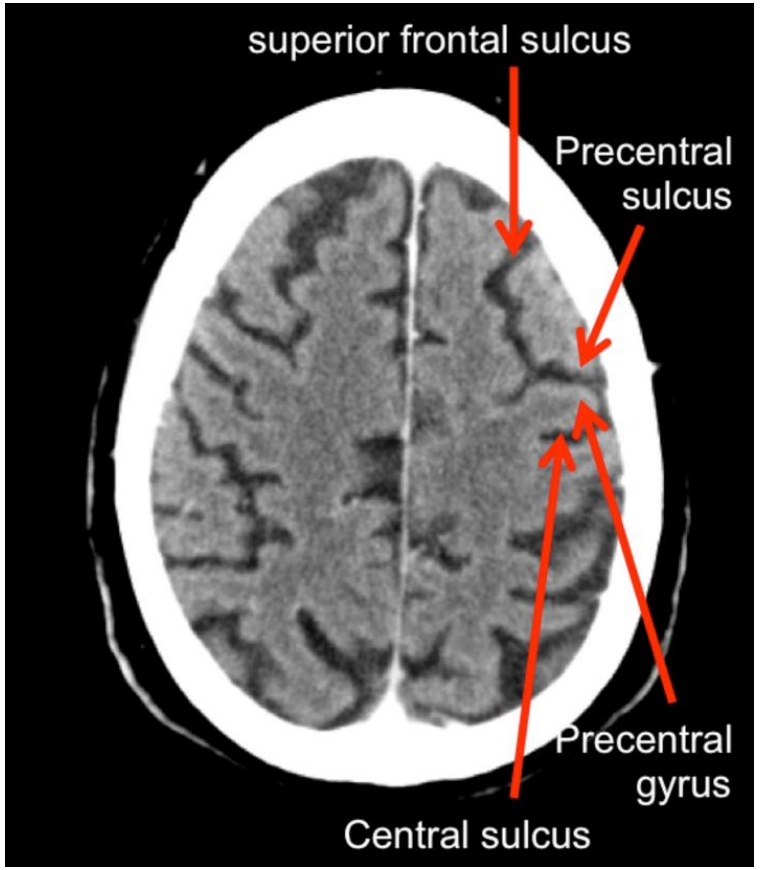

Recognizing the central sulcus

- Intraparietal sulcus at its most anterior portion gets in touch with the posterocentral sulcus

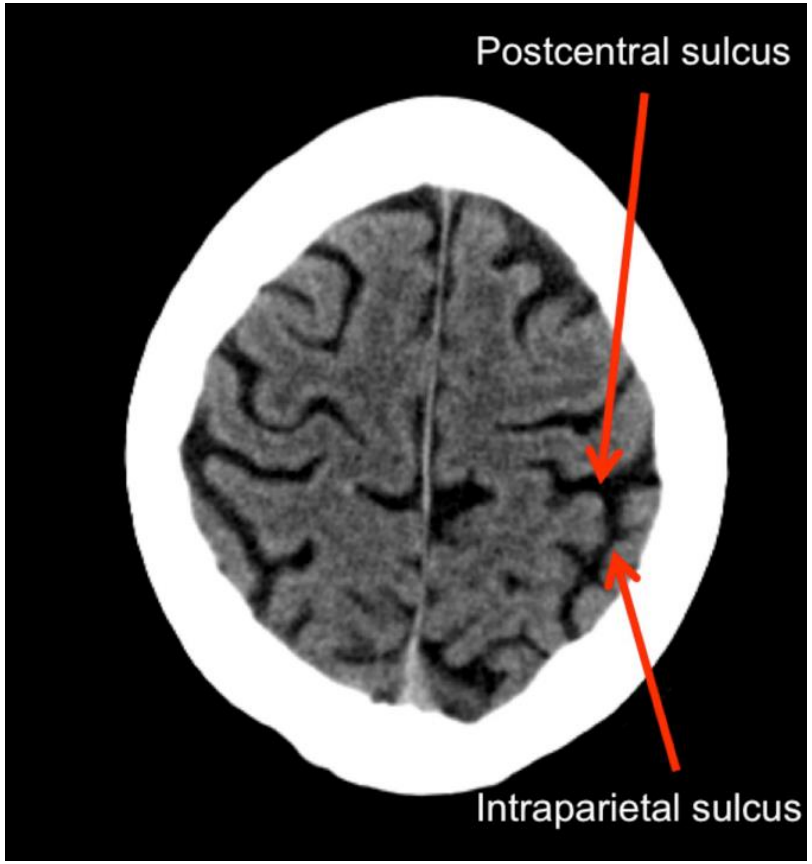

Recognizing the lateral sulcus

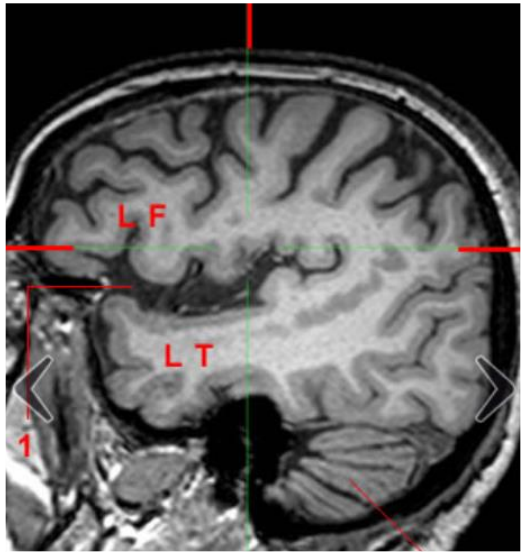

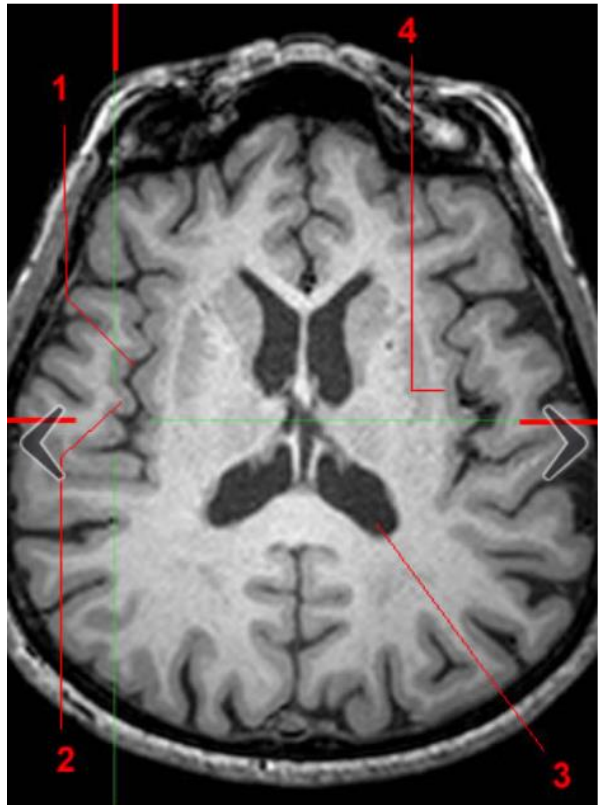

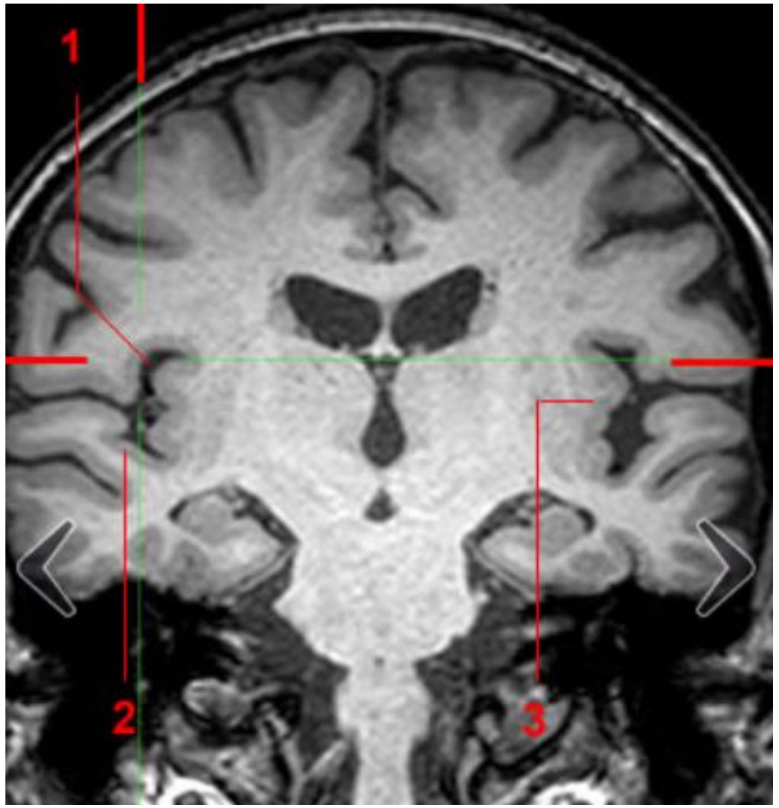

1 = lateral sulcus (sylvius)

1 = lateral sulcus
3 = lateral ventricules
4 = insula

1 = lateral sulcus
3 = insula

MRI images copied from https://www.info-radiologie.ch/irm_cerebrale.php

The frontal lobe

- Subdivision of the frontal lobe:
  - Precentral gyrus: primary motor area
    - Anterior to the CS
    - Posterior to the **pre-central sulcus**
  - Superior and Medial frontal gyrus
    - Separated by the **superior frontal sulcus**
  - Inferior frontal gyrus
    - Identification on sagittal plane (Broca area)
  - Orbital gyri
    - Identification on axial and coronal plane (motivation, emotion and social behaviour)

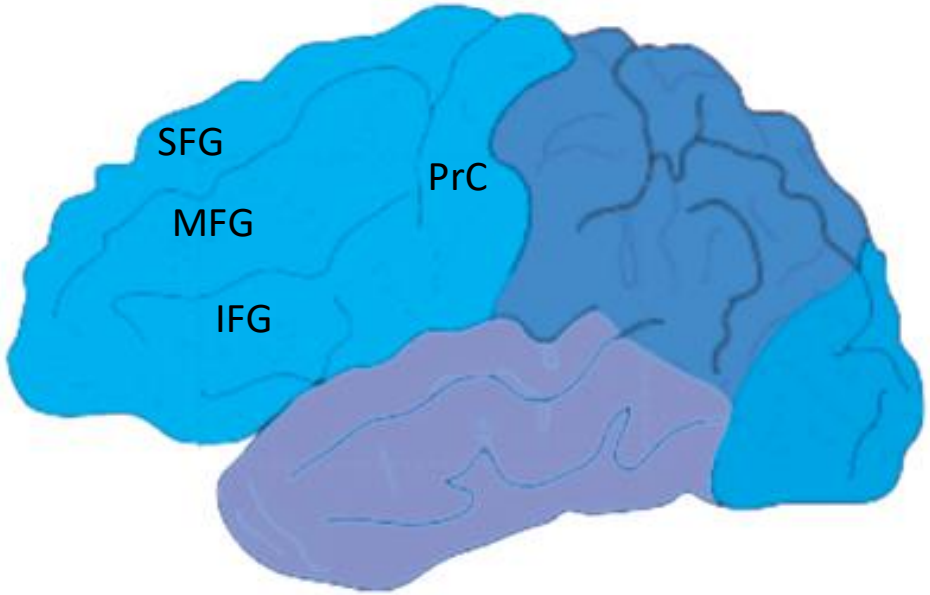

A key axial section to locate subdivisions of the frontal lobe involved in sensory-motor functions

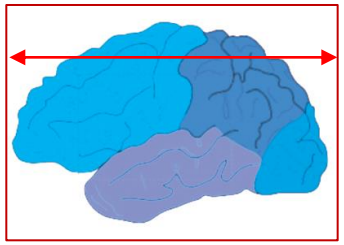

MRI image modified from:
https://www.imaios.com/fr/e-Anatomy/

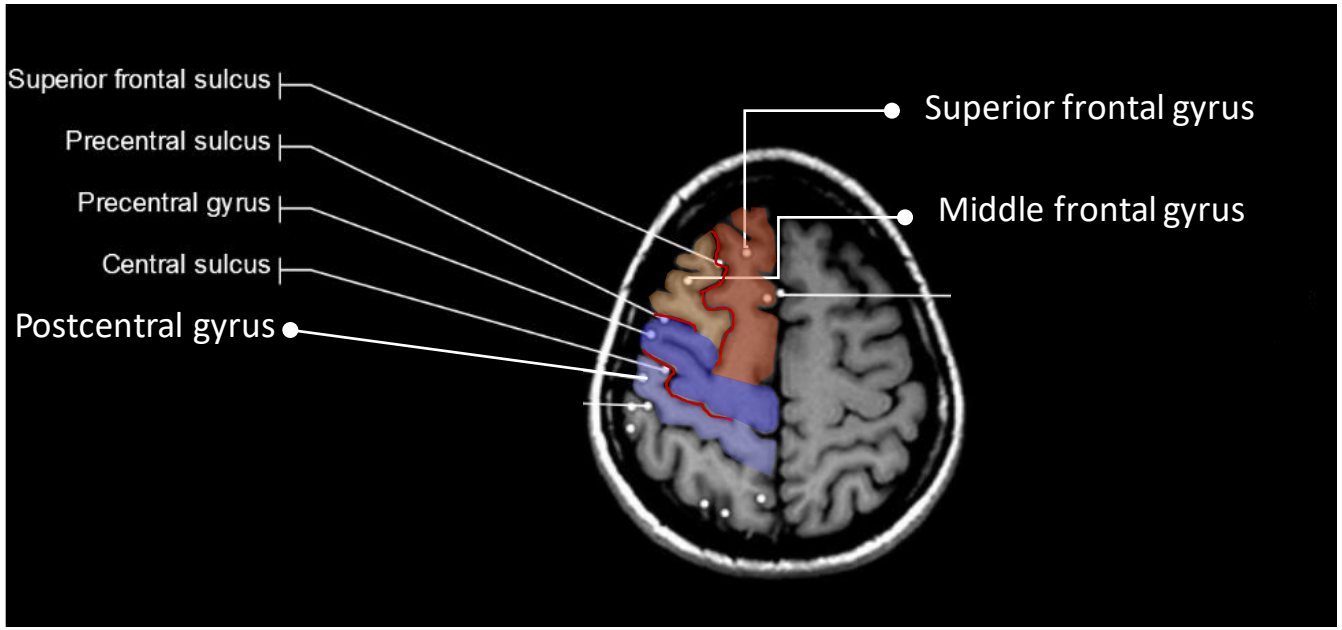

- In this key axial section, we can recognize the CS and the superior frontal sulcus
- Precentral gyrus is anterior to CS and it touches the superior frontal sulcus which delineates the superior frontal gyrus inside (suplemtary motor area) and the middle frontal gyrus outside (premotor cortex)
- CS is posterior to the precentral gyrus (primary motor area) and anterior to the post-central gyrus (primary somato-sensory area)

The inferior frontal lobe and Broca area

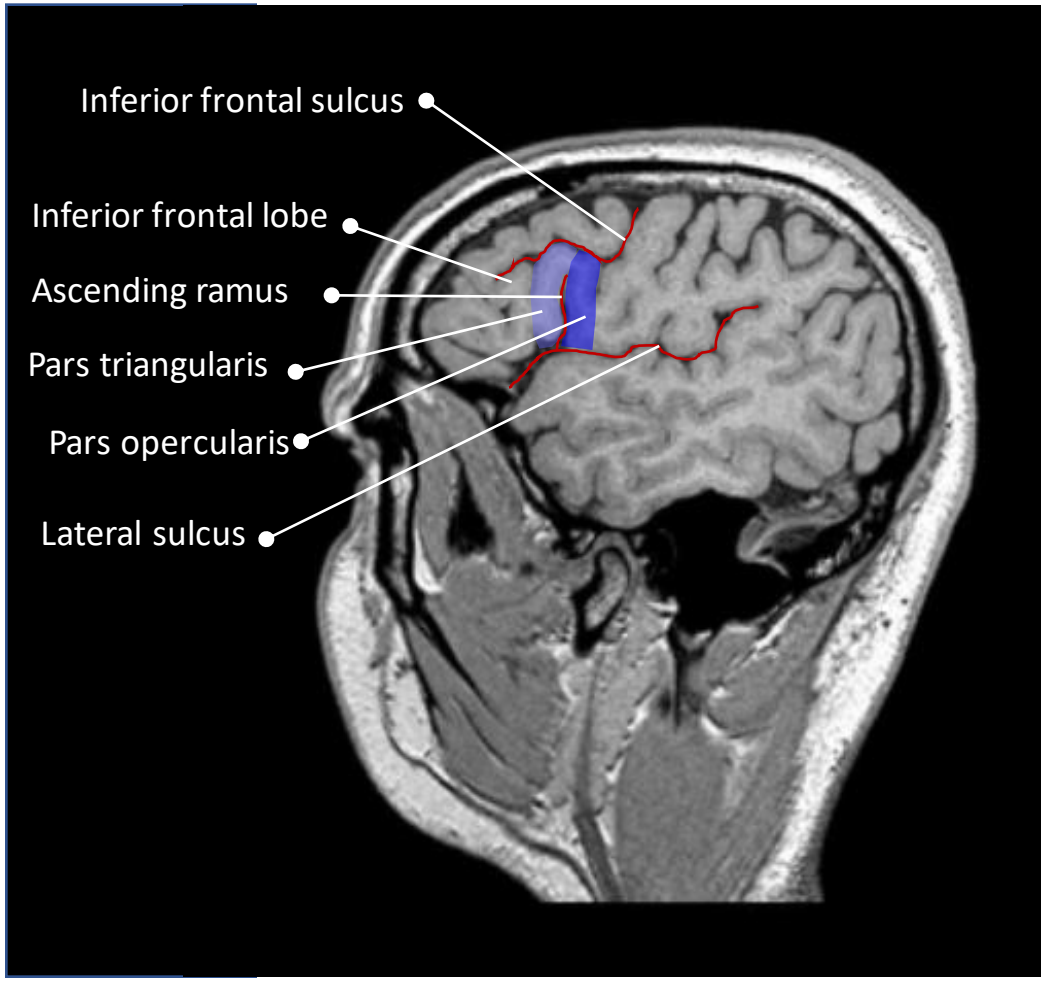

- Select the sagittal plane passing through the ascending ramus of the lateral sulcus.
- Broca area, one of the main language area in the left hemisphere is composed of pars triangularis (anterior to the ascending ramus) and pars opercularis (posterior to the ascending ramus)
- When localized on sagittal section, Broca area can be identified on axial sections

MRI image modified from: https://www.imaios.com/fr/e-Anatomy/

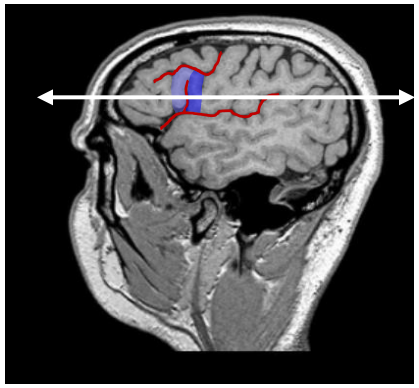

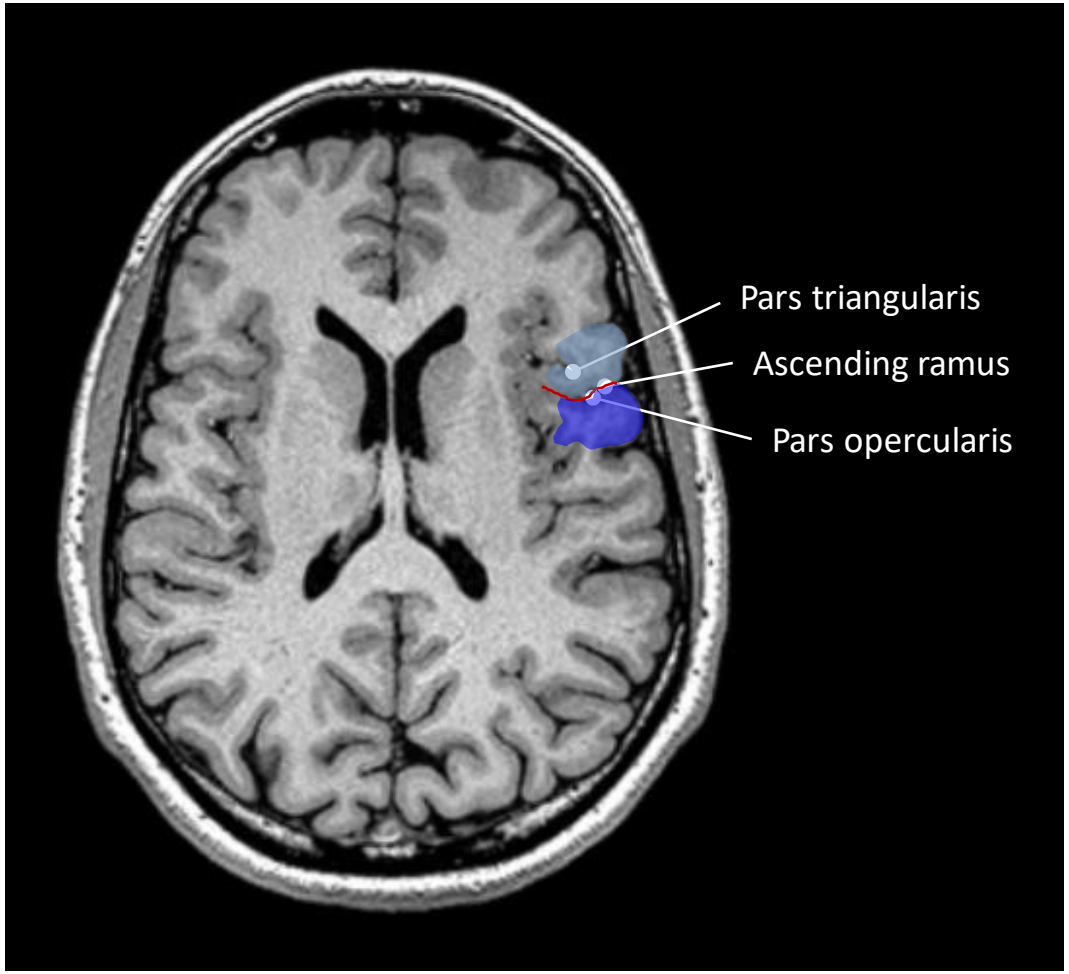

MRI images modified from: https://www.imaios.com/fr/e-Anatomy/

The temporal lobe

- Anatomical location
  - The temporal lobe is located beneath the frontal lobe separated by **the lateral sulcus** (Sylvius)
  - Delimitation with the parietal and occipital lobe is more fuzzy
  - Subdivision: the lateral surface is divided into superior, middle and inferior gyri by the superior and middle temporal sulci.
  - Functional areas:
    - Heschl gyrus (primary auditory cortex
    - Temporal plane (Wernicke area)
    - Hippocampus (memory)

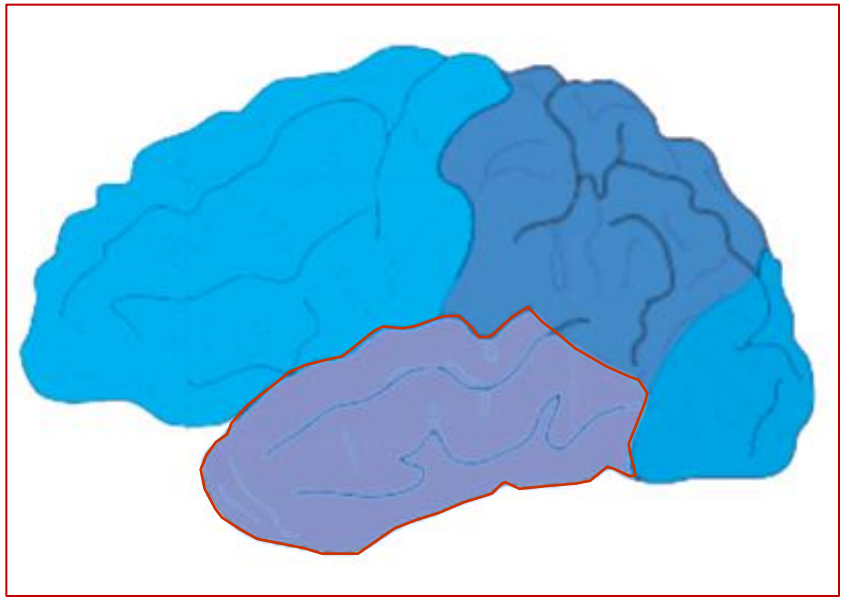

Superior, middle and inferior temporal gyri

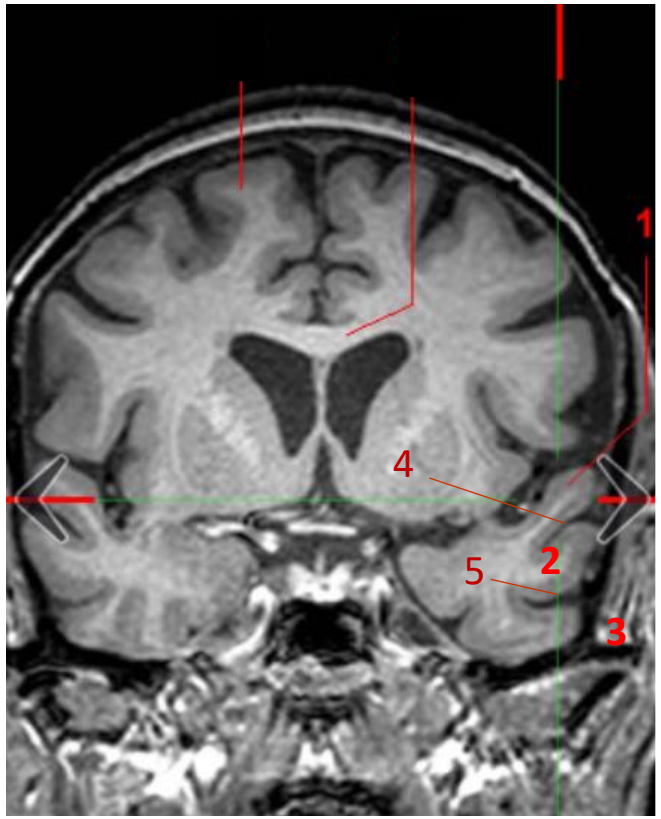

- Subdivisions of the lateral surface are easy to recognize on sagittal and coronal section with the lateral sulcus and can be secondarily identified on axial sections

1 = STG
2 = MTG
3 = ITG

4 = Superior temporal sulcus
5 = Middle temporal sulcus

MRI images copied from https://www.info-radiologie.ch/irm_cerebrale.php

Superior temporal gyrus on axial plane

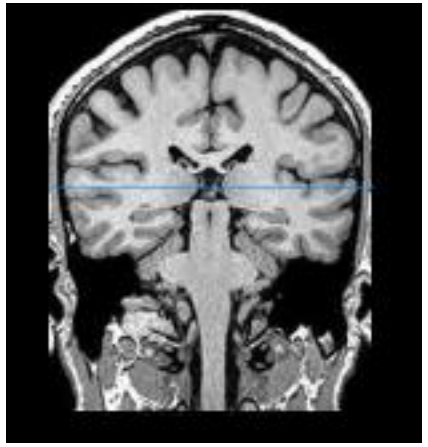

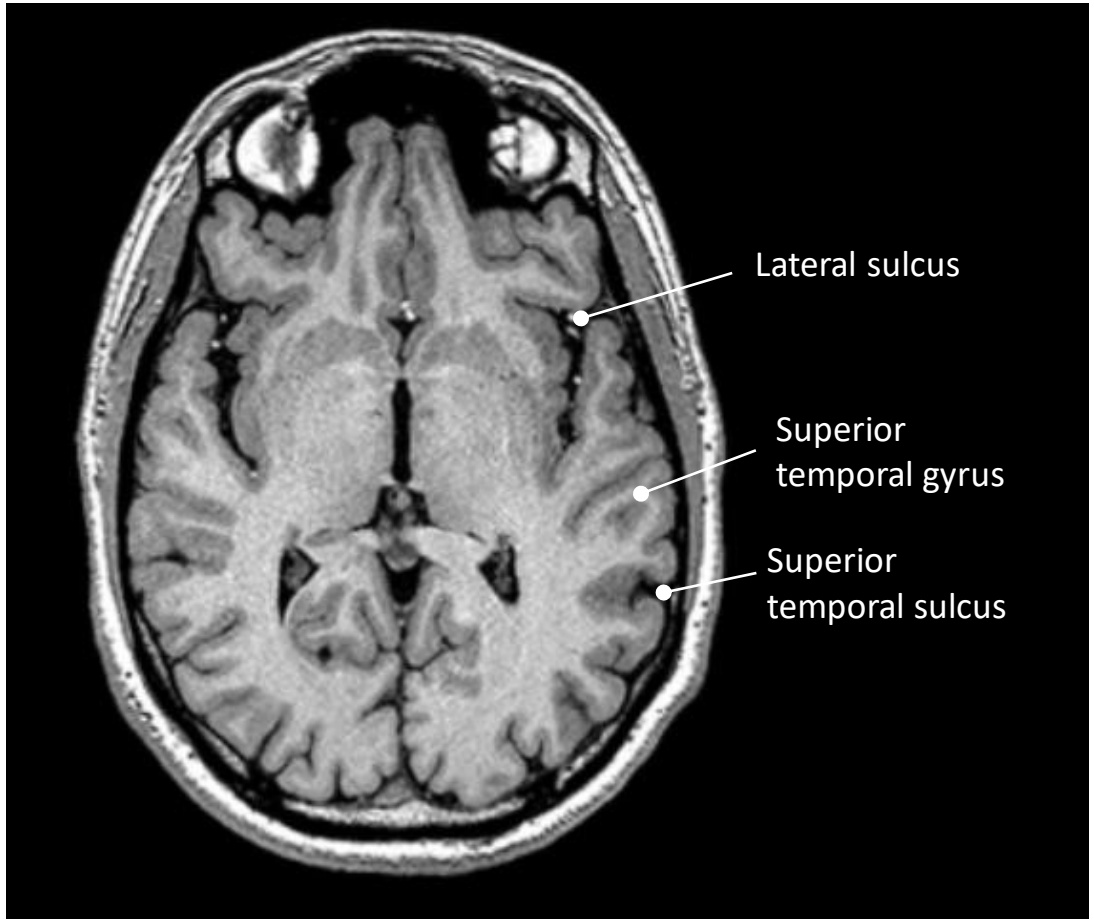

MRI images modified from: https://www.imaios.com/fr/e-Anatomy/

Superior temporal gyrus secondarily identified on axial sections using the coronal plane between the lateral sulcus and the superior temporal sulcus

Primary auditory area – BA 41, 42 (Heschl's gyrus)

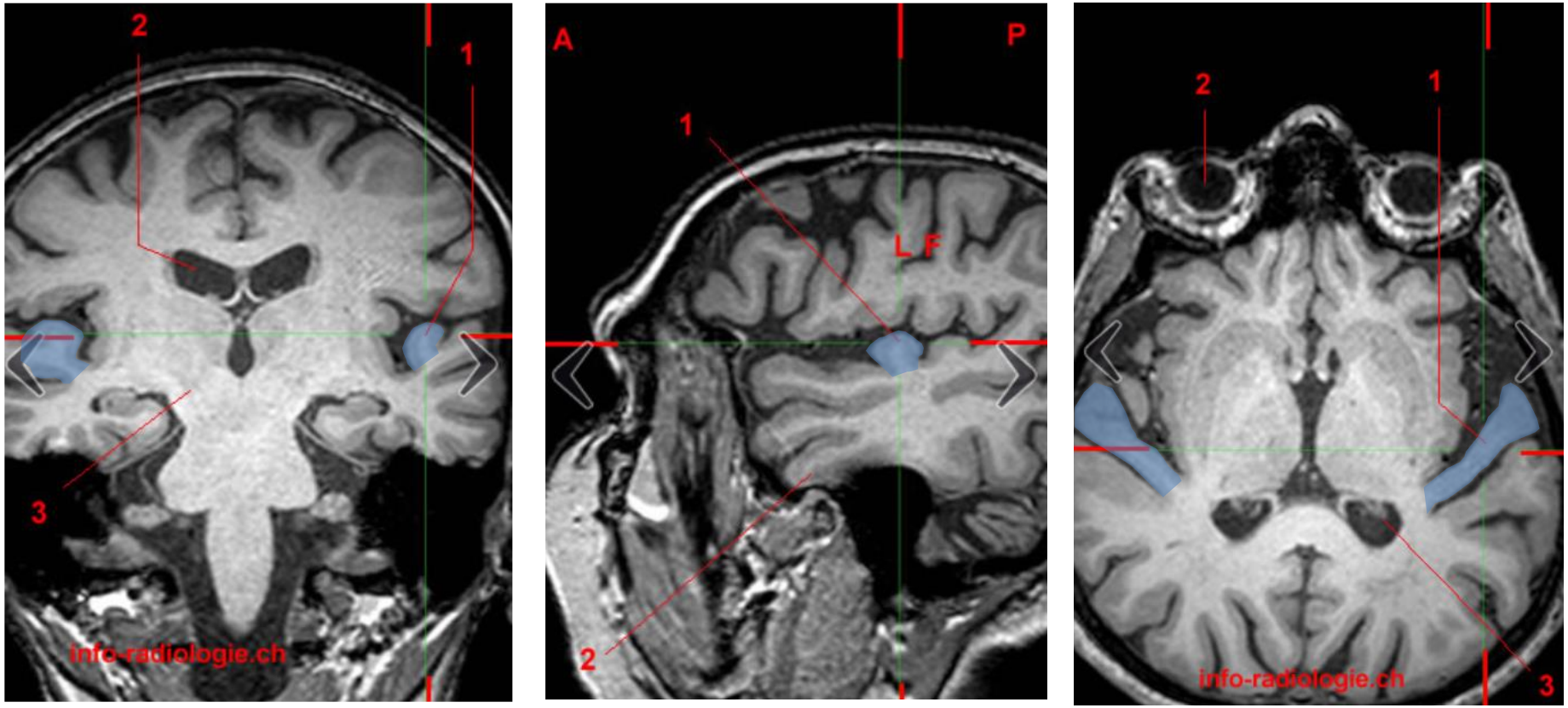

- Coronal section passing through the lateral ventricles and V3 : inside the lateral sulcus attached to the STG
- Sagittal section : HG can be viewed inside the lateral sulcus attached to the STG as either an omega shape (if one gyrus is present) or a heart shape (if two gyri and a sulcus are present) on the section passing through ocular globes
- Can be secondarily identified on axial sections

Wernicke area – left STG BA 22 – temporal plane

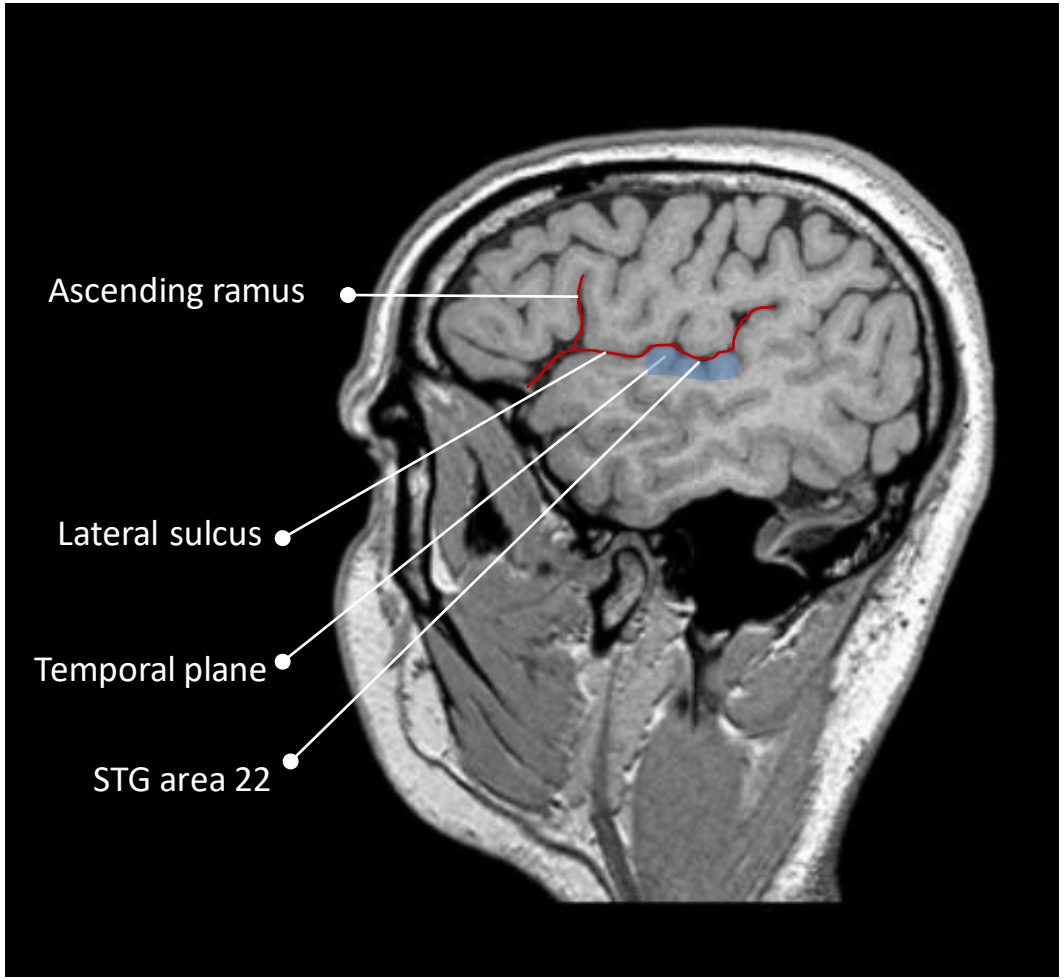

MRI images modified from:
https://www.imaios.com/fr/e-Anatomy/

- Select the sagittal plane passing through the ascending ramus of the lateral sulcus (the same as for Broca area).
- Wernicke area is located in the **temporal plane**. It is a surface of the temporal lobe, on the floor of the lateral sulcus, part of the STG (BA 22), posterior to the primary auditory cortex and anterior to the inferior parietal lobule.

Wernicke area – left STG BA 22 – temporal plane

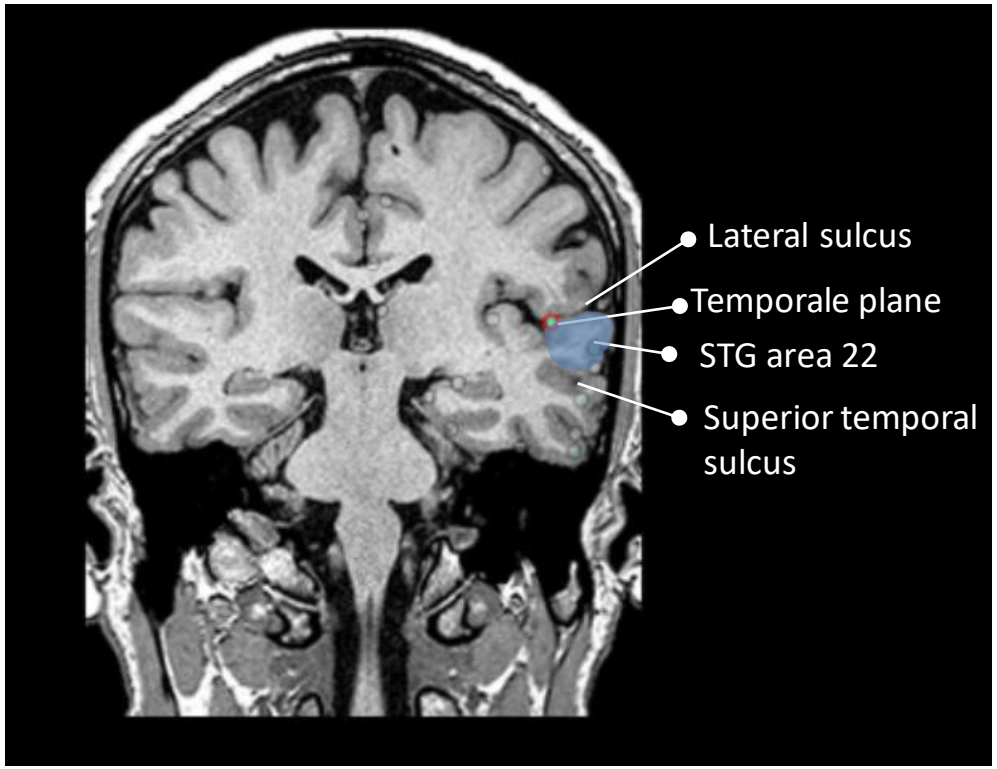

MRI images modified from:
https://www.imaios.com/fr/e-Anatomy/

- Coronal plane passing through the VL, V3 and the pedoncles. The floor of the lateral sulcus is horizontal (plane) at this level of the STG (BA 22).

Wernicke area – left STG BA 22 – temporal plane

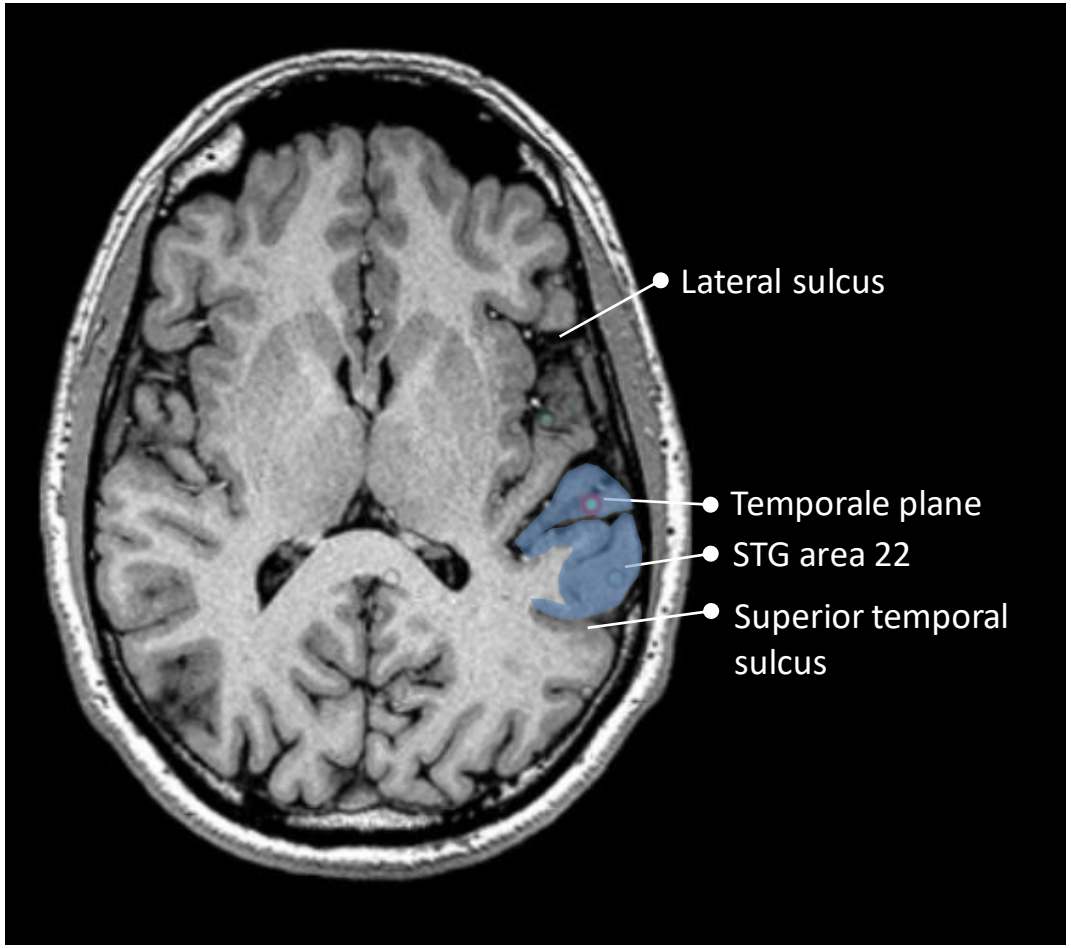

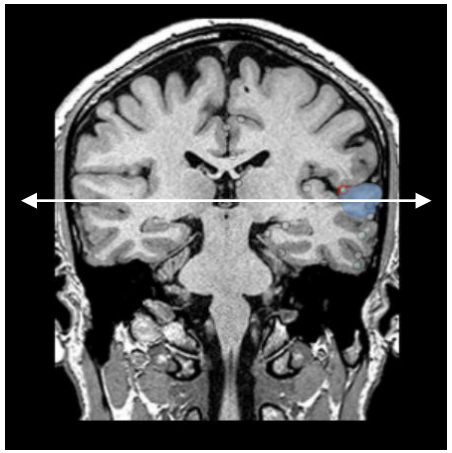

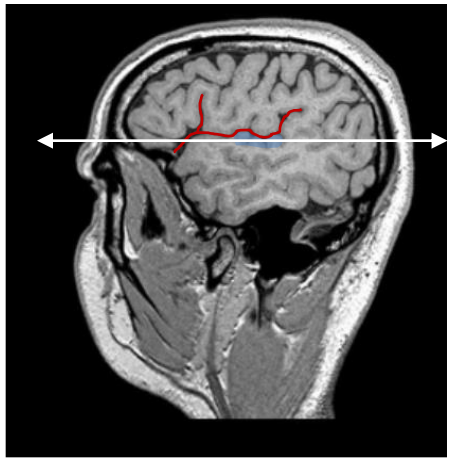

MRI images modified from: https://www.imaios.com/fr/e-Anatomy/

Internal surface of the temporal lobe and hippocampus

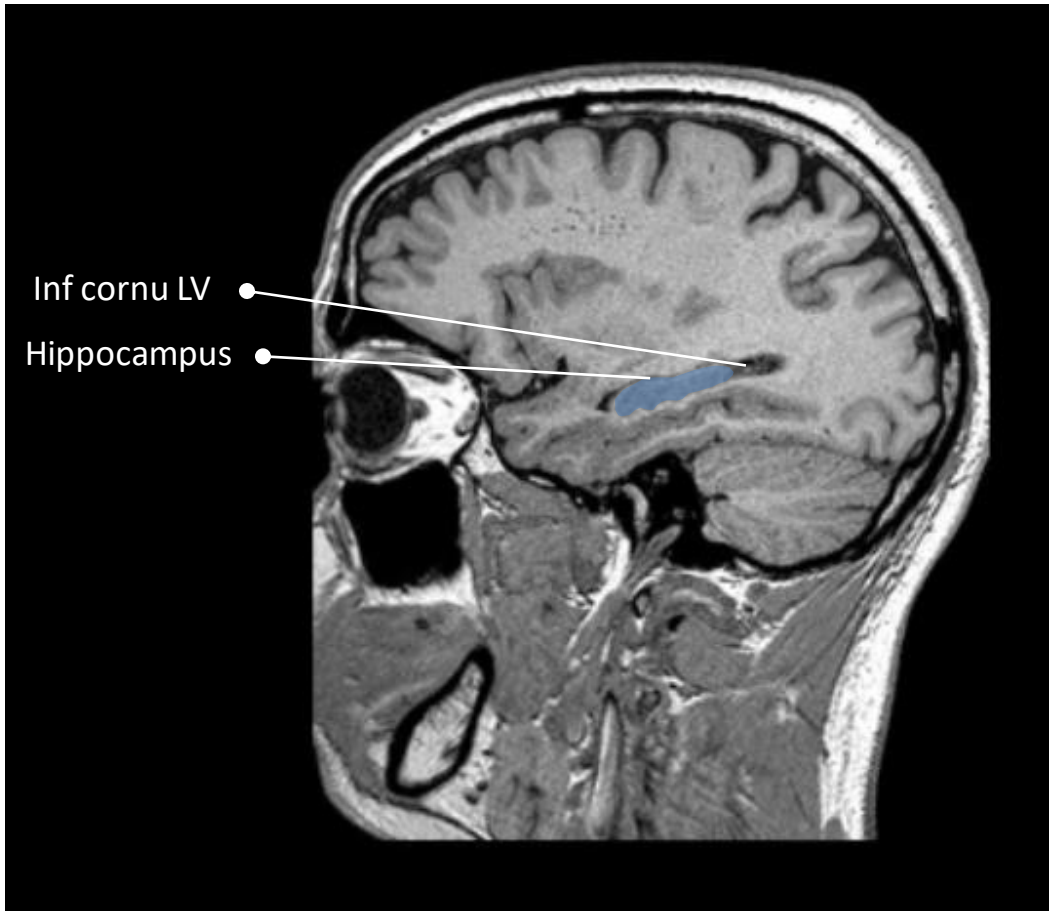

- Sagittal plane passing through ocular globes: the hippocampus is a curved eminence of gray matter which extends throughout the entire length of the floor of the inferior cornu of the VL in the internal part of the temporal lobe.

MRI images modified from: https://www.imaios.com/fr/e-Anatomy/

Internal surface of the temporal lobe and hippocampus

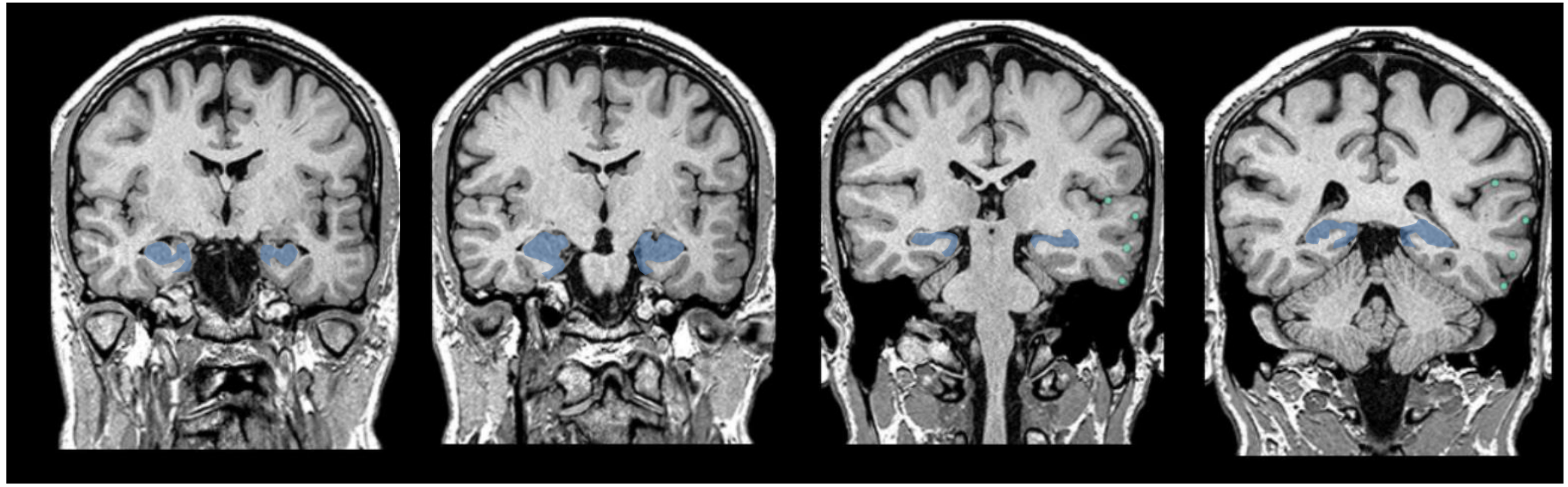

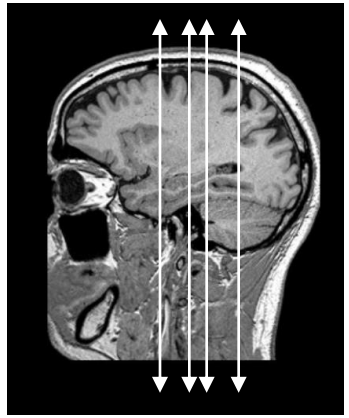

- Coronal plane: the hippocampus is a curved eminence of gray matter which extends throughout the entire length of the floor of the inferior cornu of the VL in the internal part of the temporal lobe

MRI images modified from: https://www.imaios.com/fr/e-Anatomy/

Internal surface of the temporal lobe and hippocampus

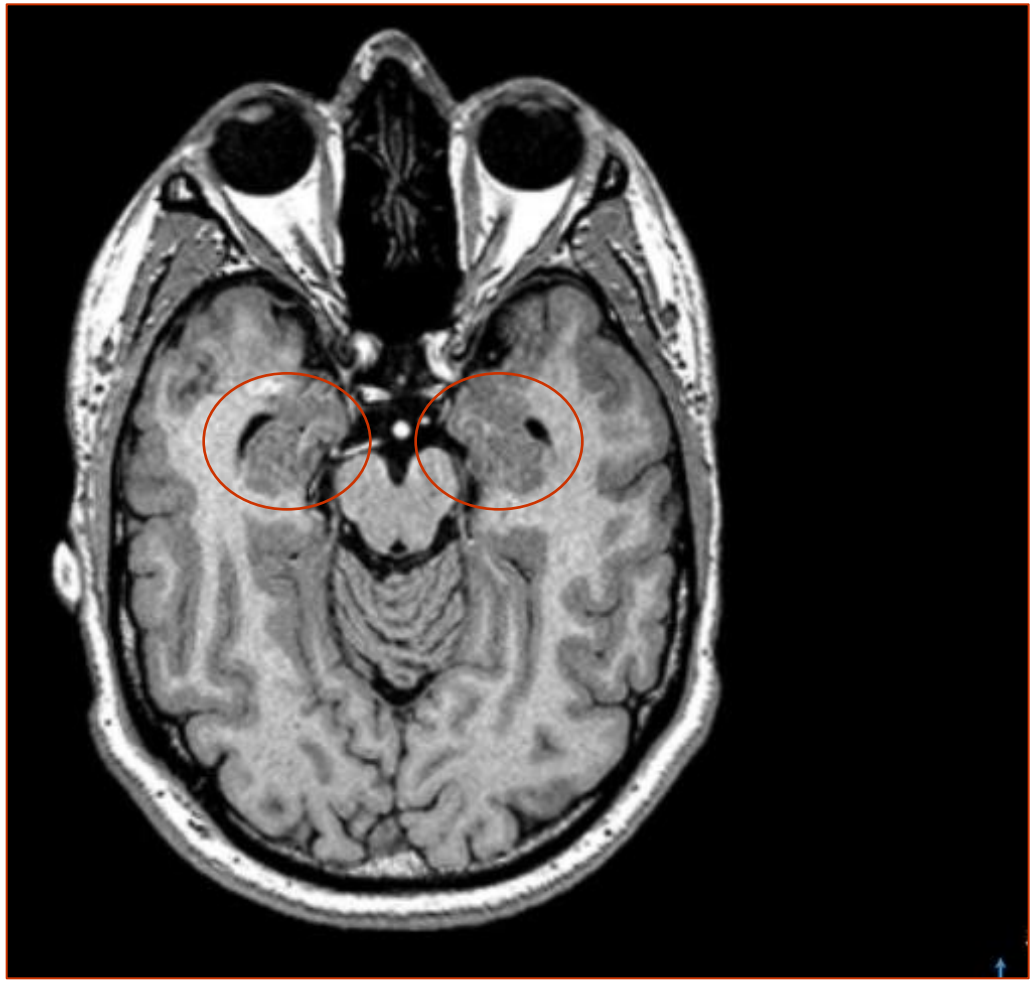

- Axial plane passing through ocular globes: the hippocampus is a curved eminence of gray matter lateral to the mesencephalon in the internal temporal lobe

MRI images modified from: https://www.imaios.com/fr/e-Anatomy/

Papez circuit and memory

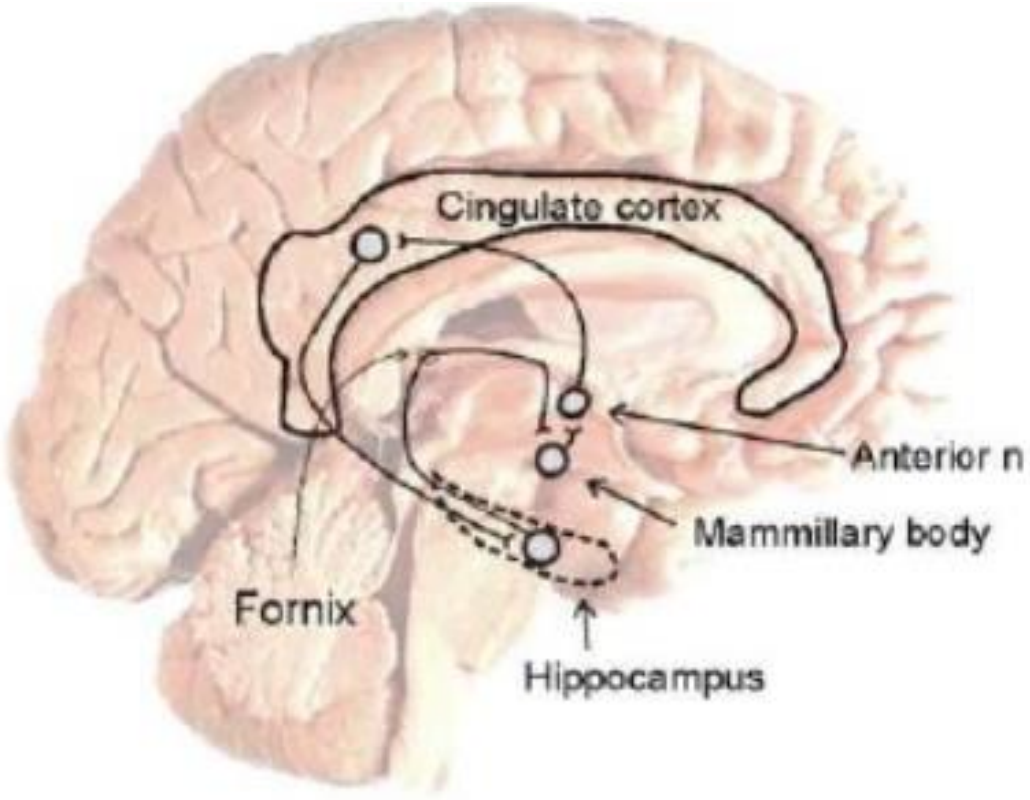

- Hippocampus is a key region for memory processing especially for encoding and restitution of events

Copied from Dr Kenira J. Thompson
Ponce School of Medicine Dept of physiology

The parietal lobe

- Anatomical location
  - The parietal lobe is separated from the frontal lobe anteriorly by the central sulcus.
  - Posteriorly, it is separated from the occipital lobe by the parieto-occipital sulcus
  - Below, it is separated from the temporal lobe by the posterior ramus of the lateral sulcus and by a line carried backword toward the pre-occipital notch

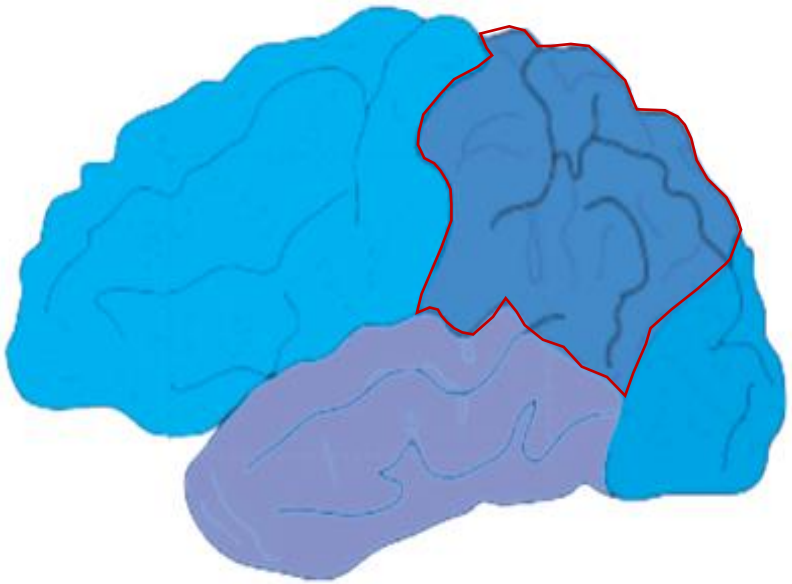

Find the central sulcus

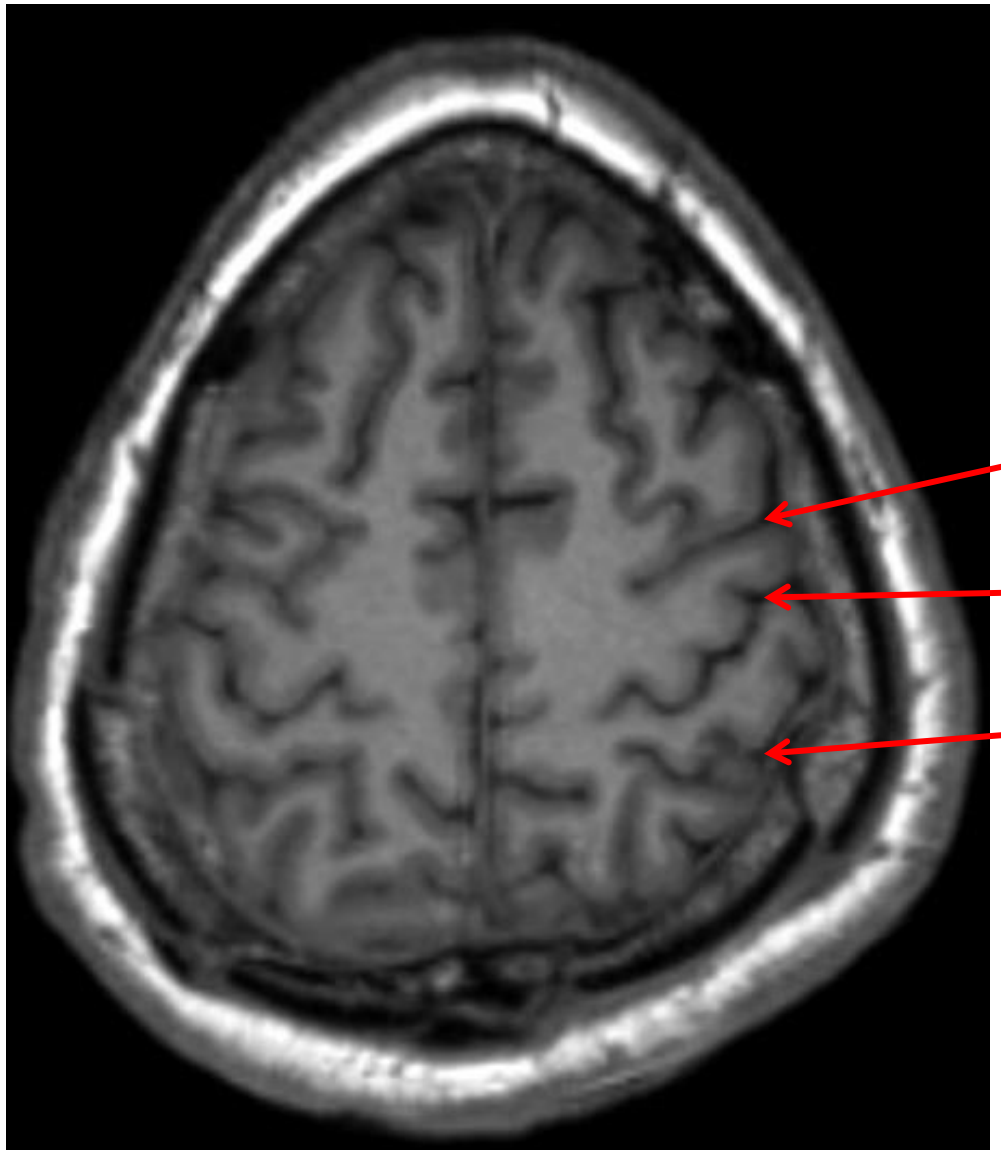

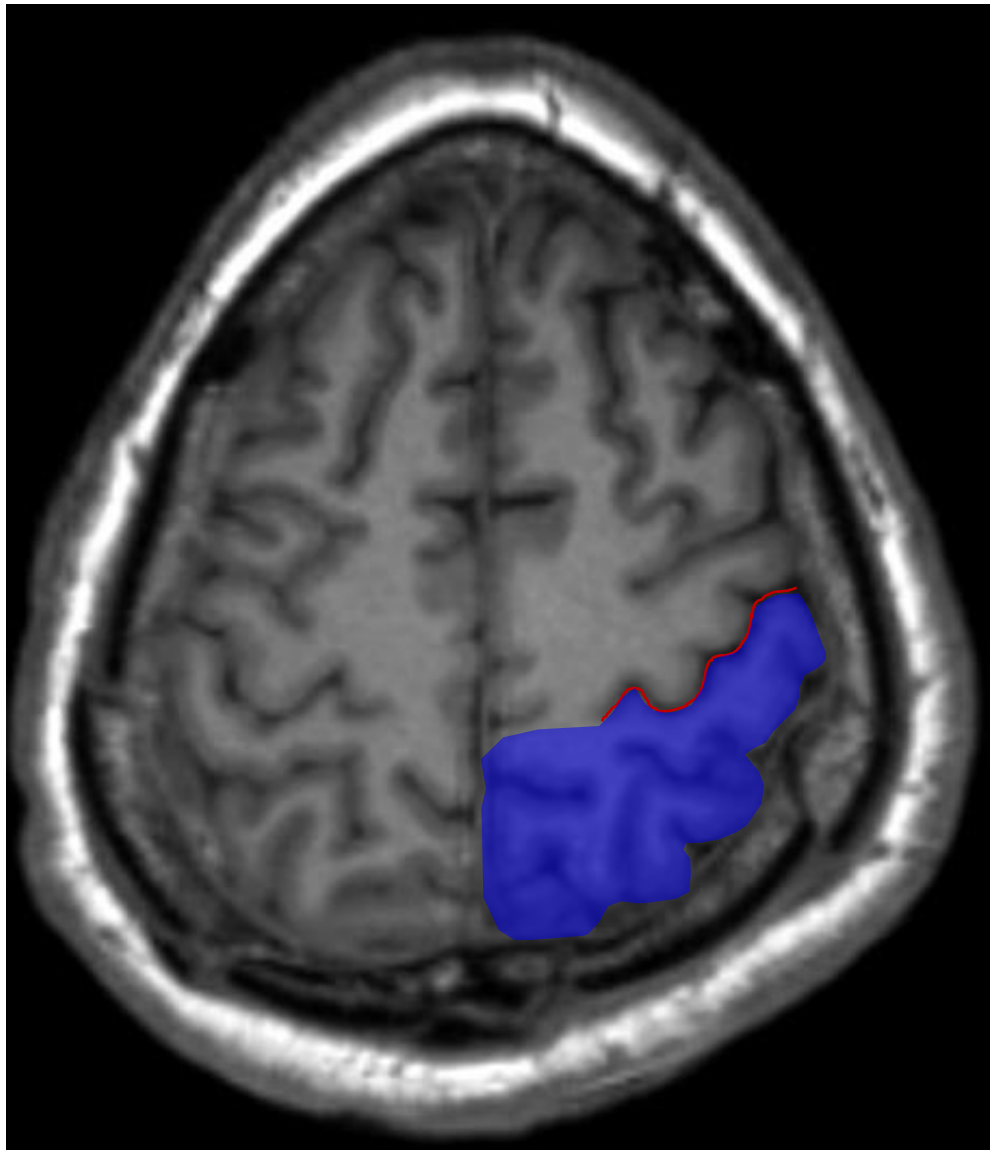

- The parietal lobe is behind the central sulcus

The parieto-occipital sulcus

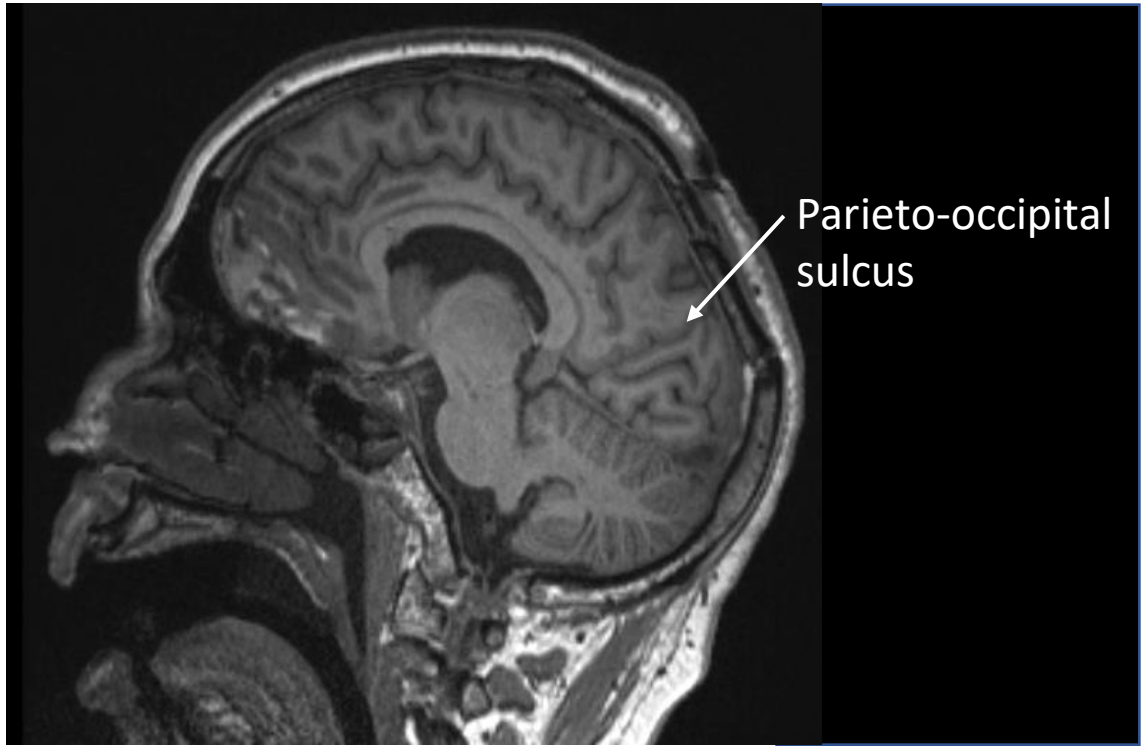

- The parieto-occipital sulcus separates the parietal lobe and the occipital lobes. Only a small part is seen on the lateral surface (lateral part); the major part (medial) is located on the medial surface and can be easily recognized on a medial sagittal plane

The parieto-occipital sulcus

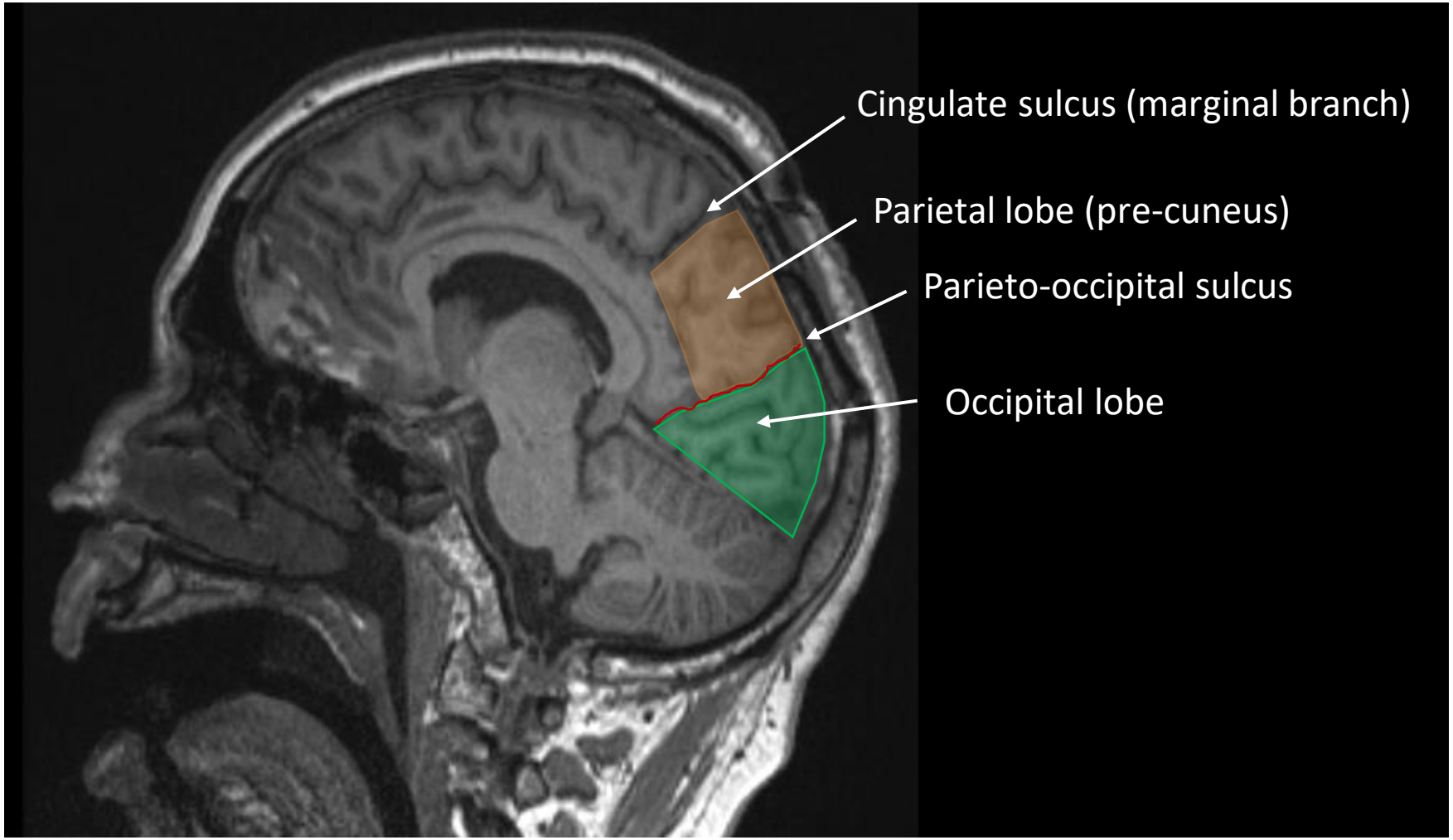

Important subdivisions of the parietal lobe

- Post-central gyrus (somato-sensory primary cortex) with the paracentral lobule
- Superior parietal lobule (dorsal visual path: vision for action) and the Pre-cuneus (body awareness)
- Inferior parietal lobule with the supra-marginalis and angular gyri involved in language processing (left) and visuo-spatial integration (right)

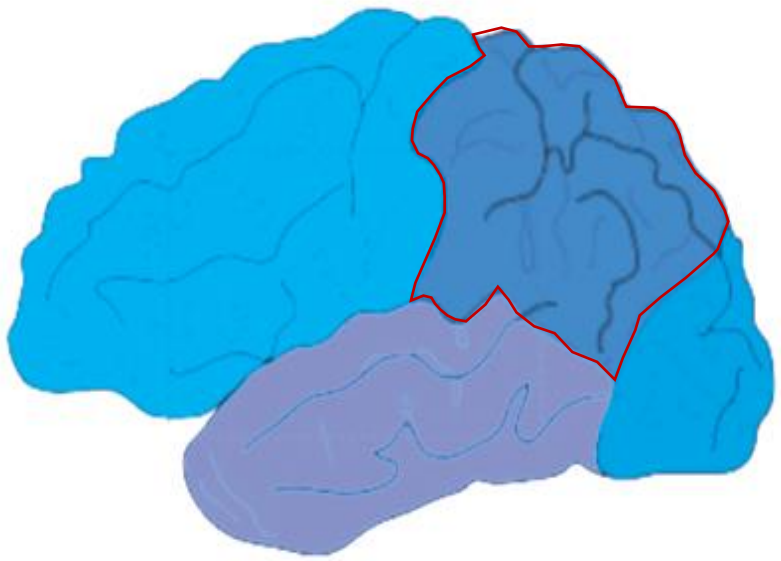

Post-central gyrus

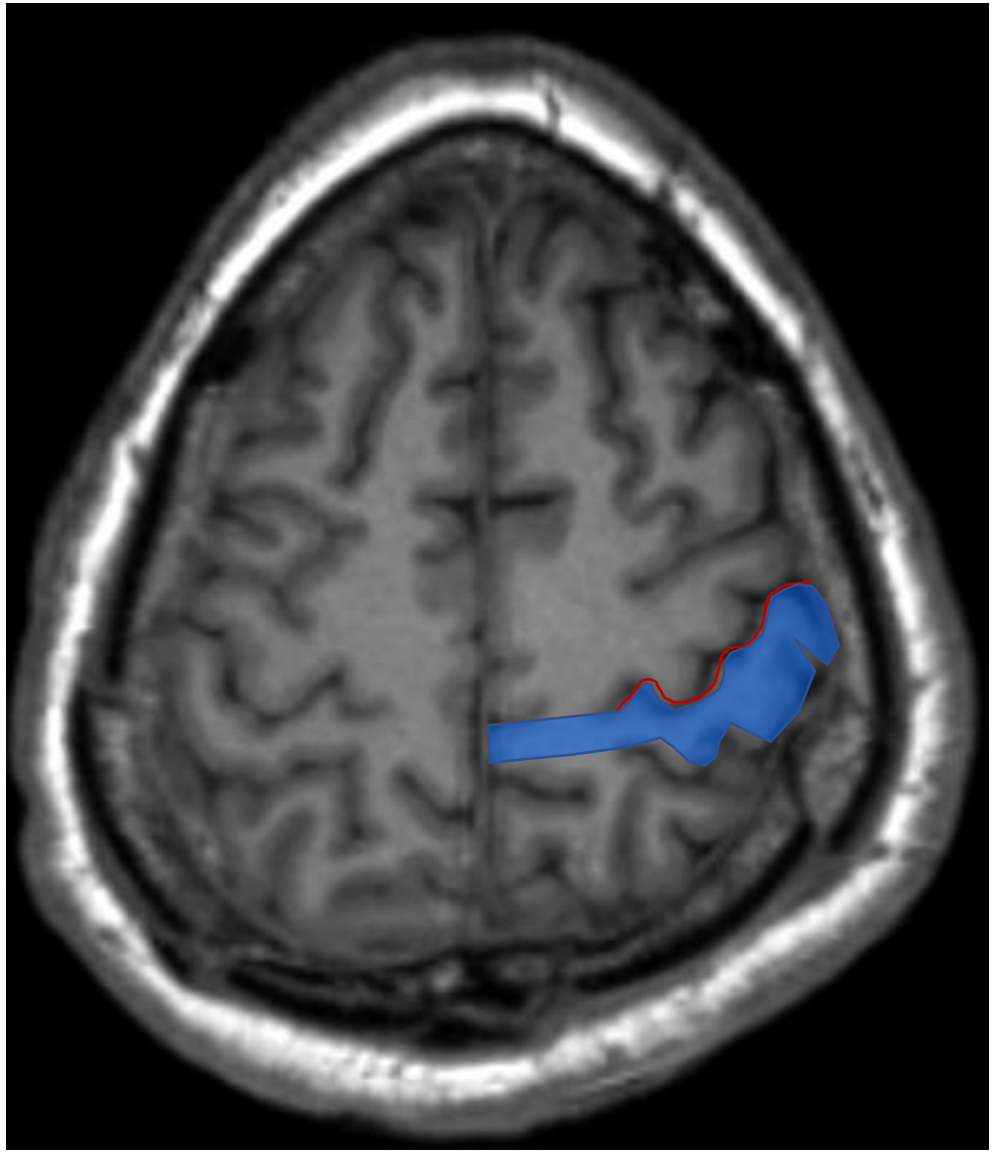

- Location: Behind the central sulcus.
- Function : Somato-senory primary cortex.
- Pathology: controlateral somato-sensory impairment
- Somatotopy of the body (somato-sensory homonculs)

Para-central gyrus

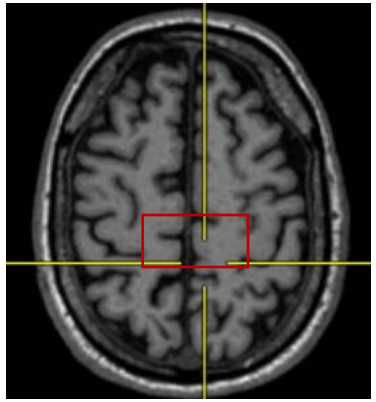

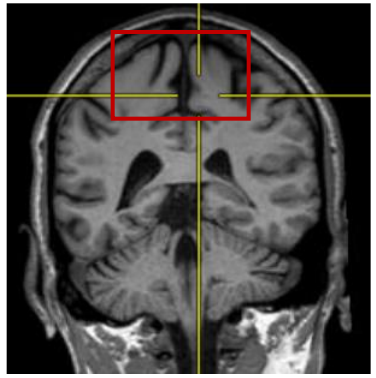

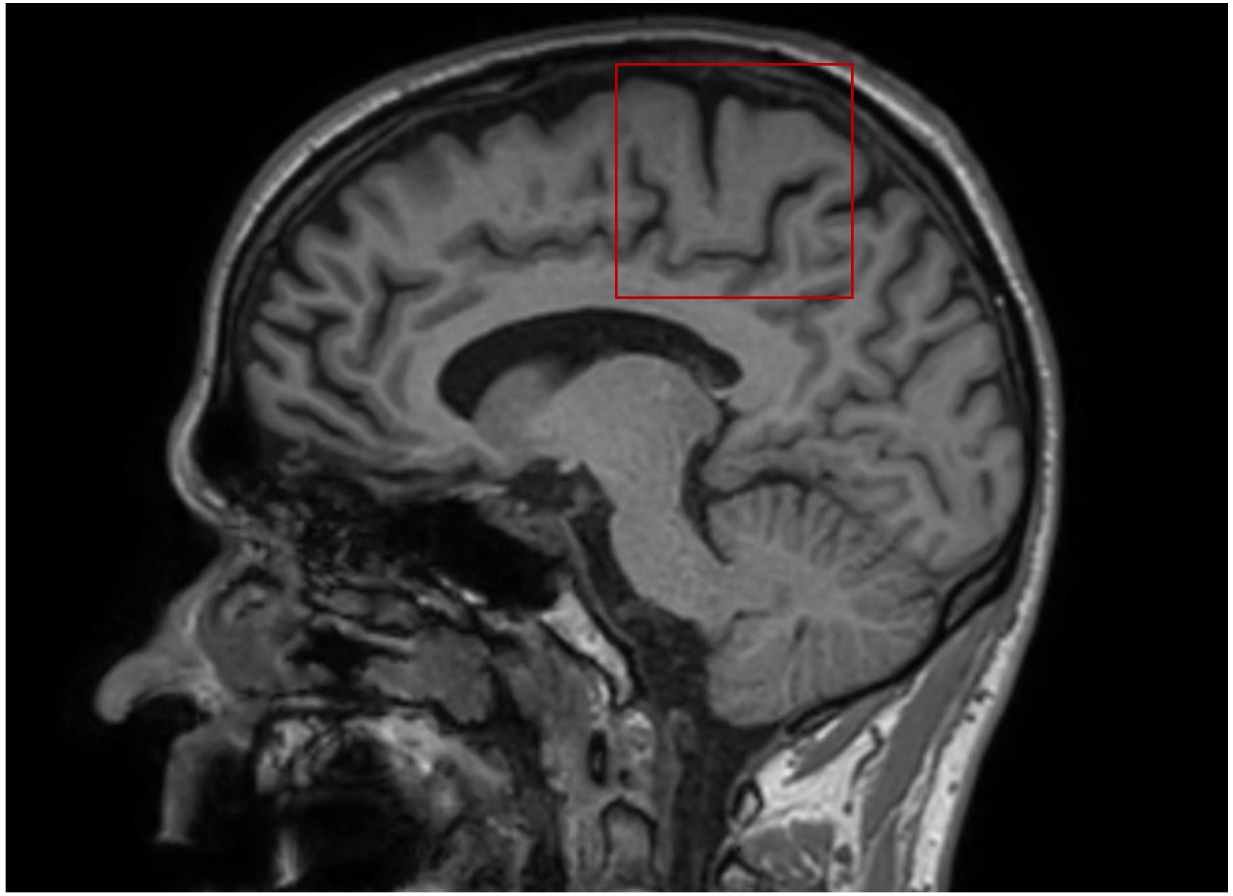

- Location: on the sagittal plane: in front of the cingulate sulcus, stands on the CS, looks like a teeth

Para-central gyrus

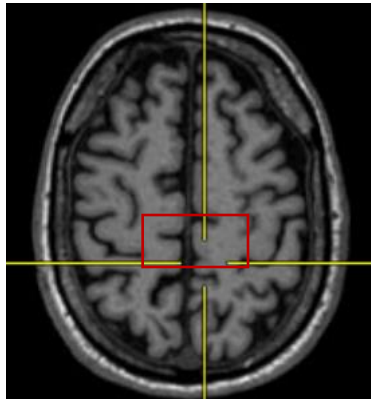

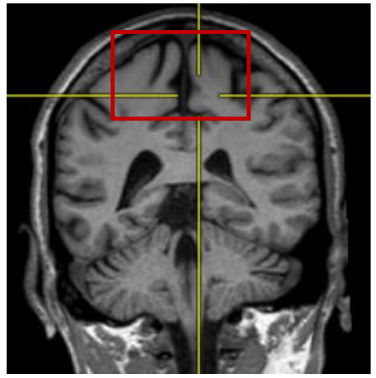

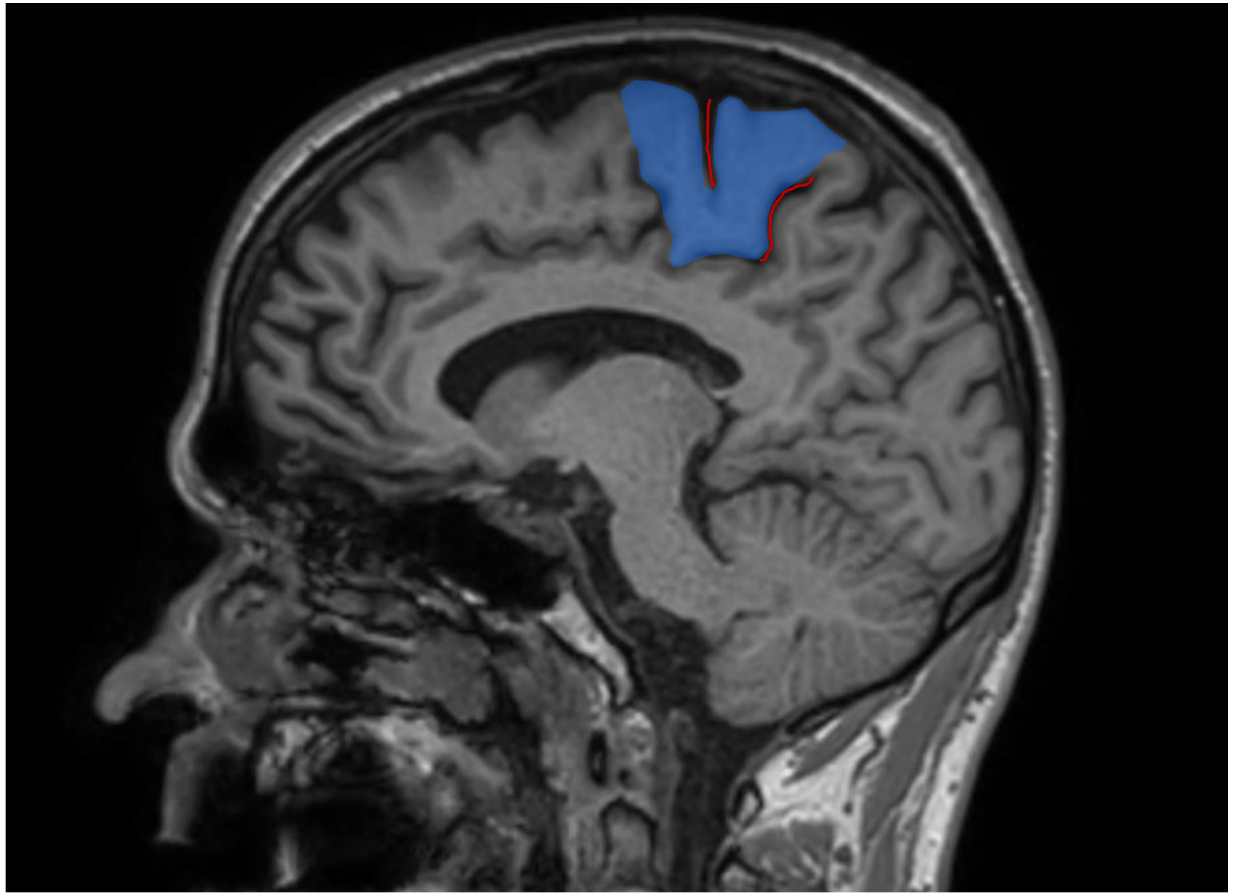

- Function : ?
- Pathology: ?

Para-central gyrus

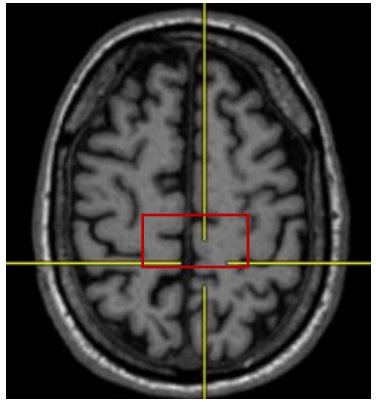

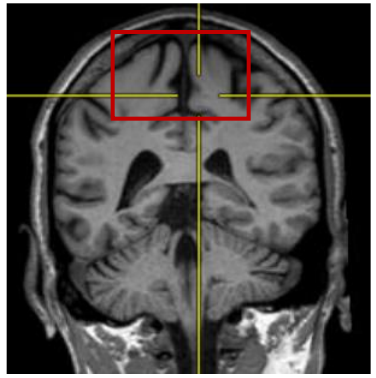

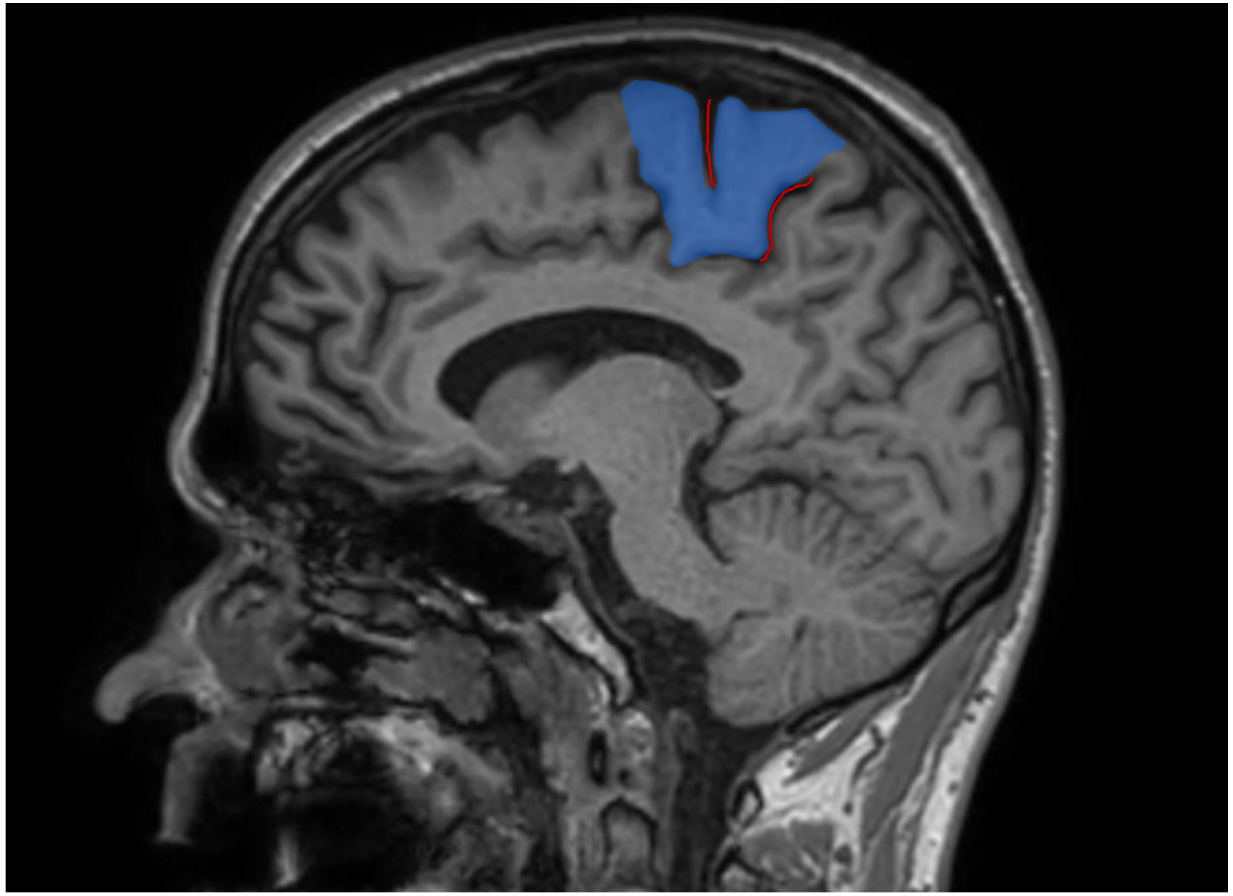

- Function : sensory motor representation of the leg
- Pathology: diplegia (from brain origin)

Posterior parietal cortex : Superior and inferior parietal lobules

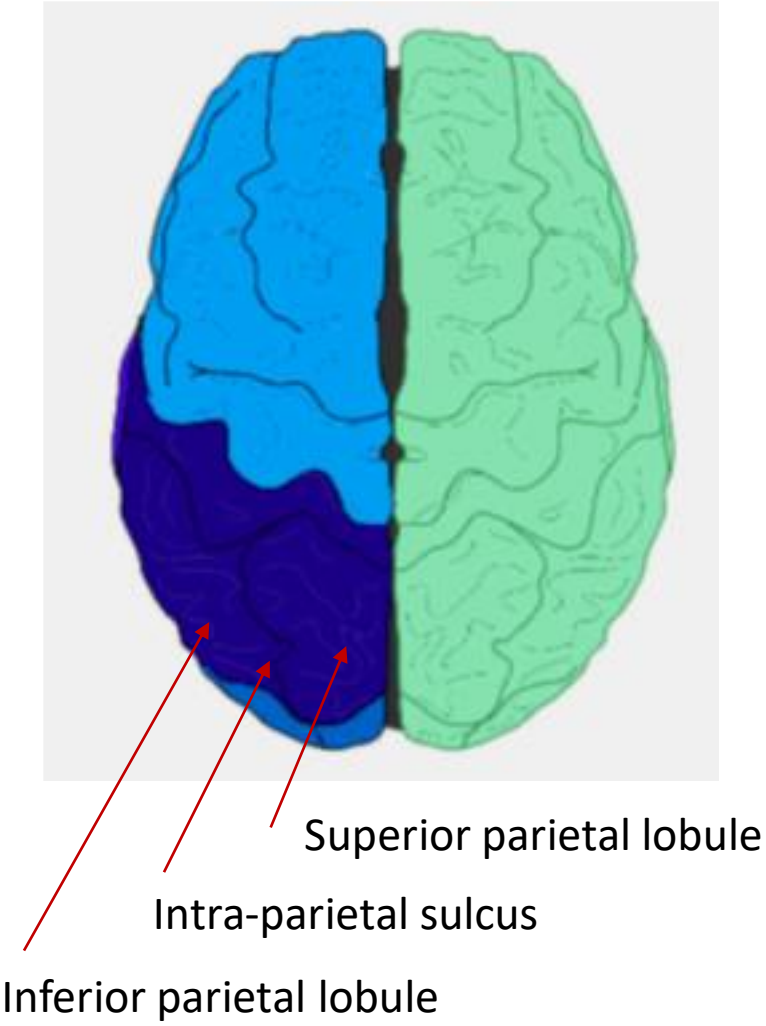

- The superior and inferior parietal lobules are separated by **the intra-parietal sulcus** which is located on the lateral surface of the parietal lobe
- Superior parietal lobule
  - Above the IPS
  - Function: dorsal visual path
  - Impairment: optic ataxia
- Inferior parietal lobule
  - Beneath the IPS
  - Function:
  - Right hemisphere : visuo-spatial integration => Neglect
  - Left hemisphere: semantic processing

Recognizing the IP sulcus

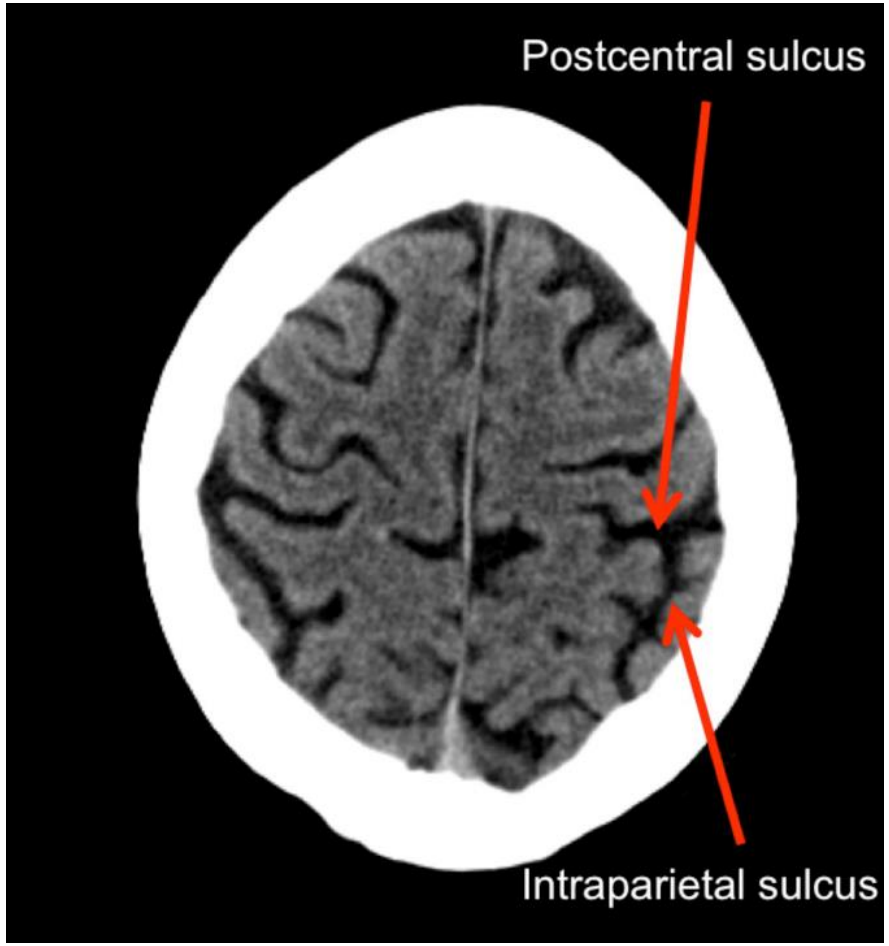

- Axial plane: Intraparietal sulcus at its most anterior portion gets in touch with the posterocentral sulcus

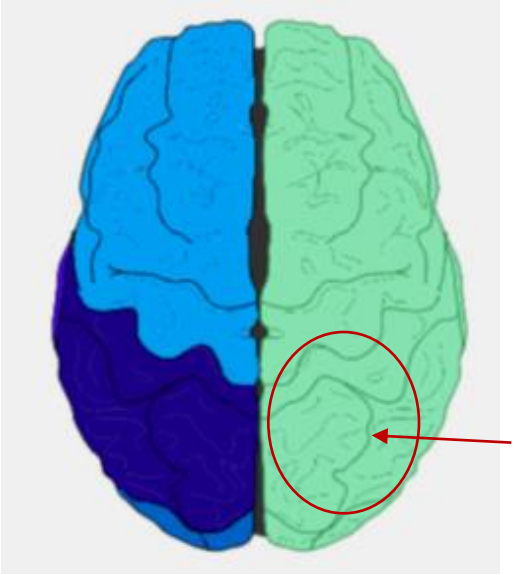

Superior parietal lobule

Intra-parietal sulcus

Inferior parietal lobule

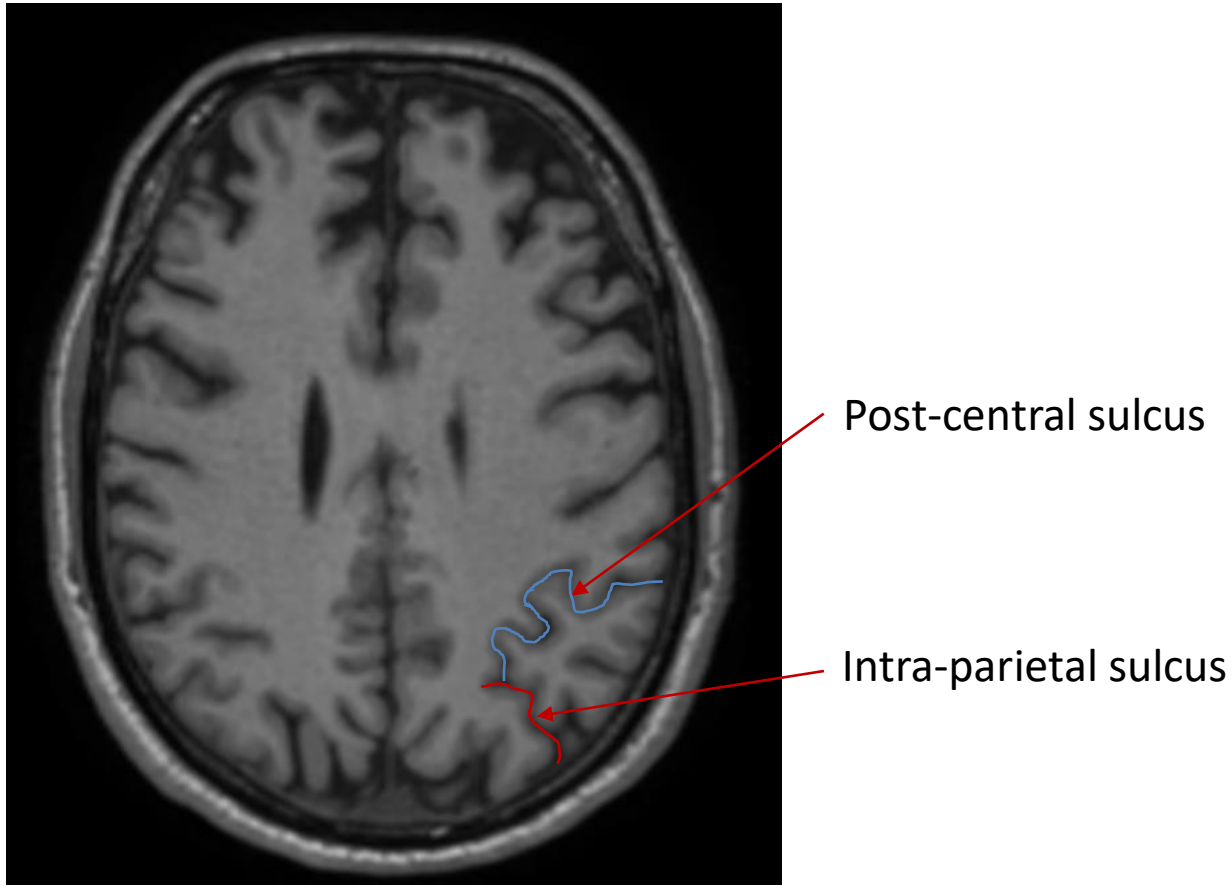
Post-central sulcus
Intra-parietal sulcus

The occipital lobe

- Anatomical location
  - The occipital lobe is posterior to the parietal and temporal lobes. The lateral surface is limited in front by the parieto-occipital sulcus and by a line carried from the end of this sulcus to the pre-occipital notch.
  - The cuneus (primary visual cortex) is located between the parieto-occipital lobe and the calcarine sulcus

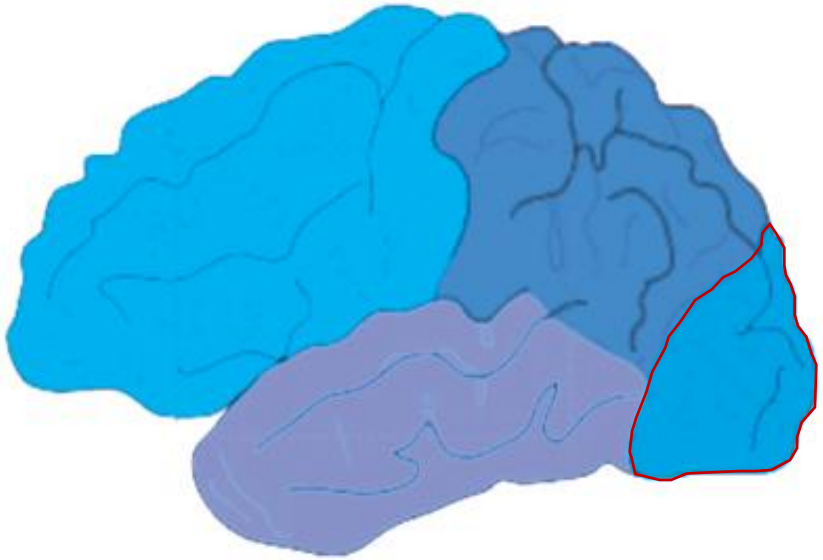

Cuneus

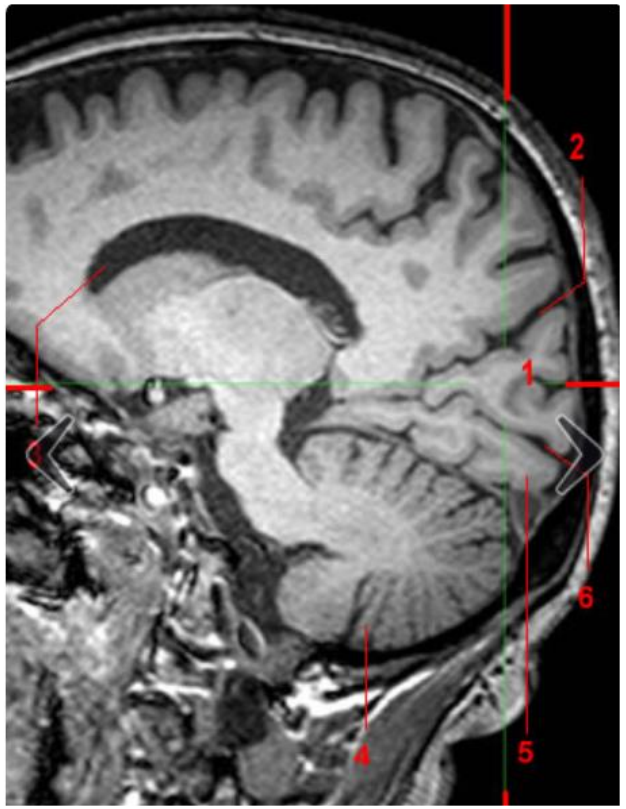

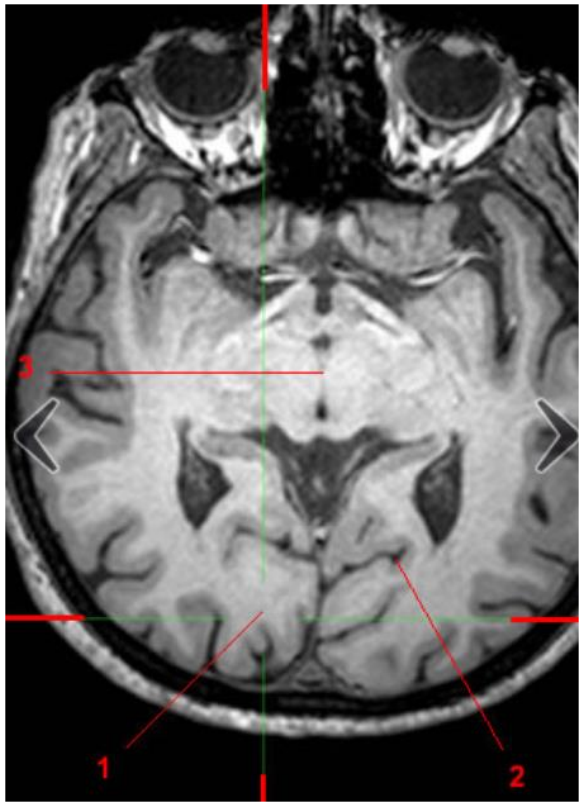

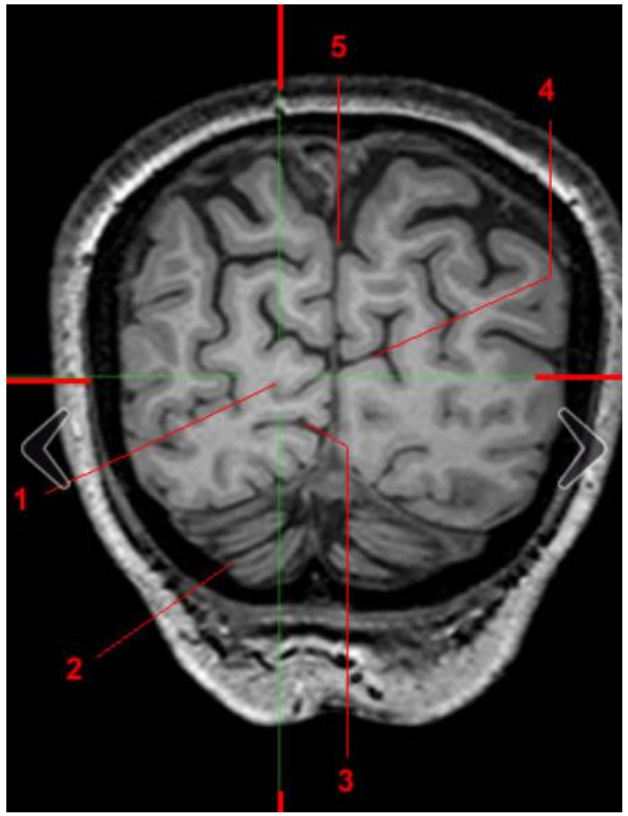

1 = Cuneus
2 = Parieto-occipital sulcus
5 = Lingual gyrus
6 = Calcarine sulcus

1 = Cuneus
2 = Parieto-occipital sulcus

1 = Cuneus
3 = Calcarine sulcus
4 = Parieto-occipital sulcus

MRI images copied from https://www.info-radiologie.ch/irm_cerebrale.php

Corpus callosum

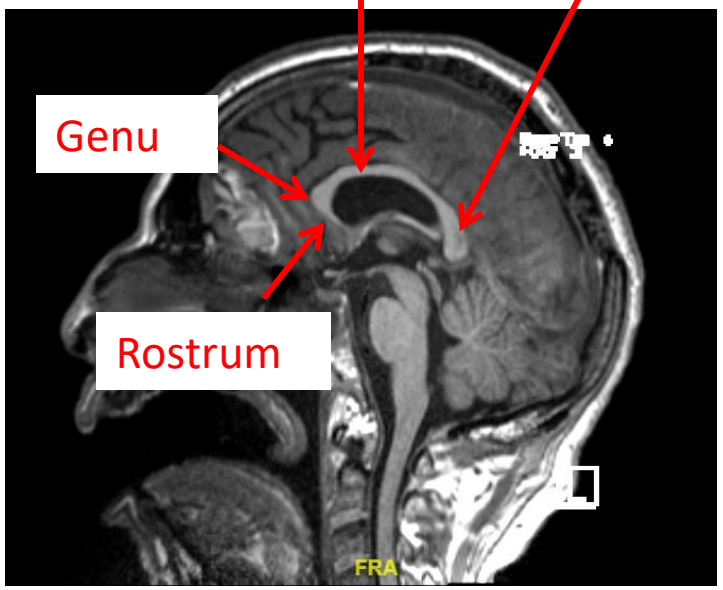

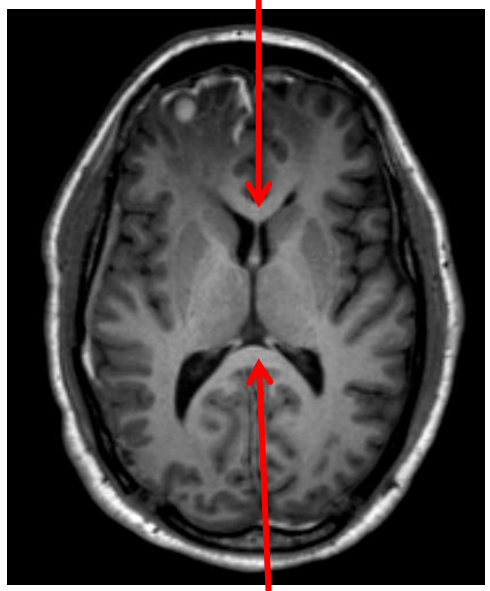

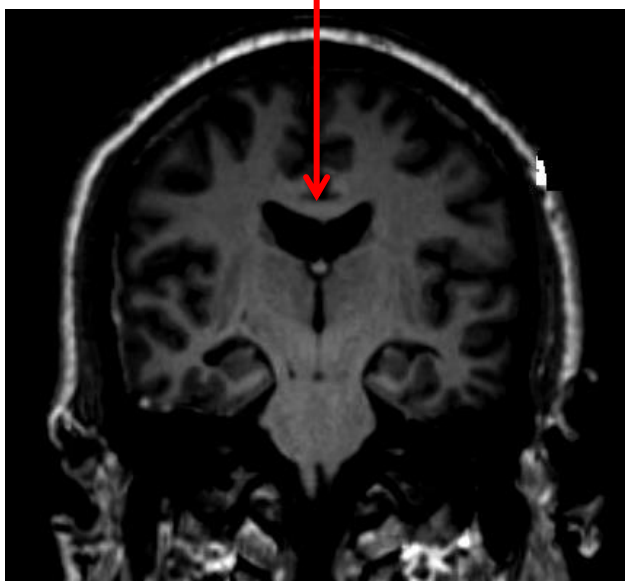

Sub-cortical regions on the horizontal plane

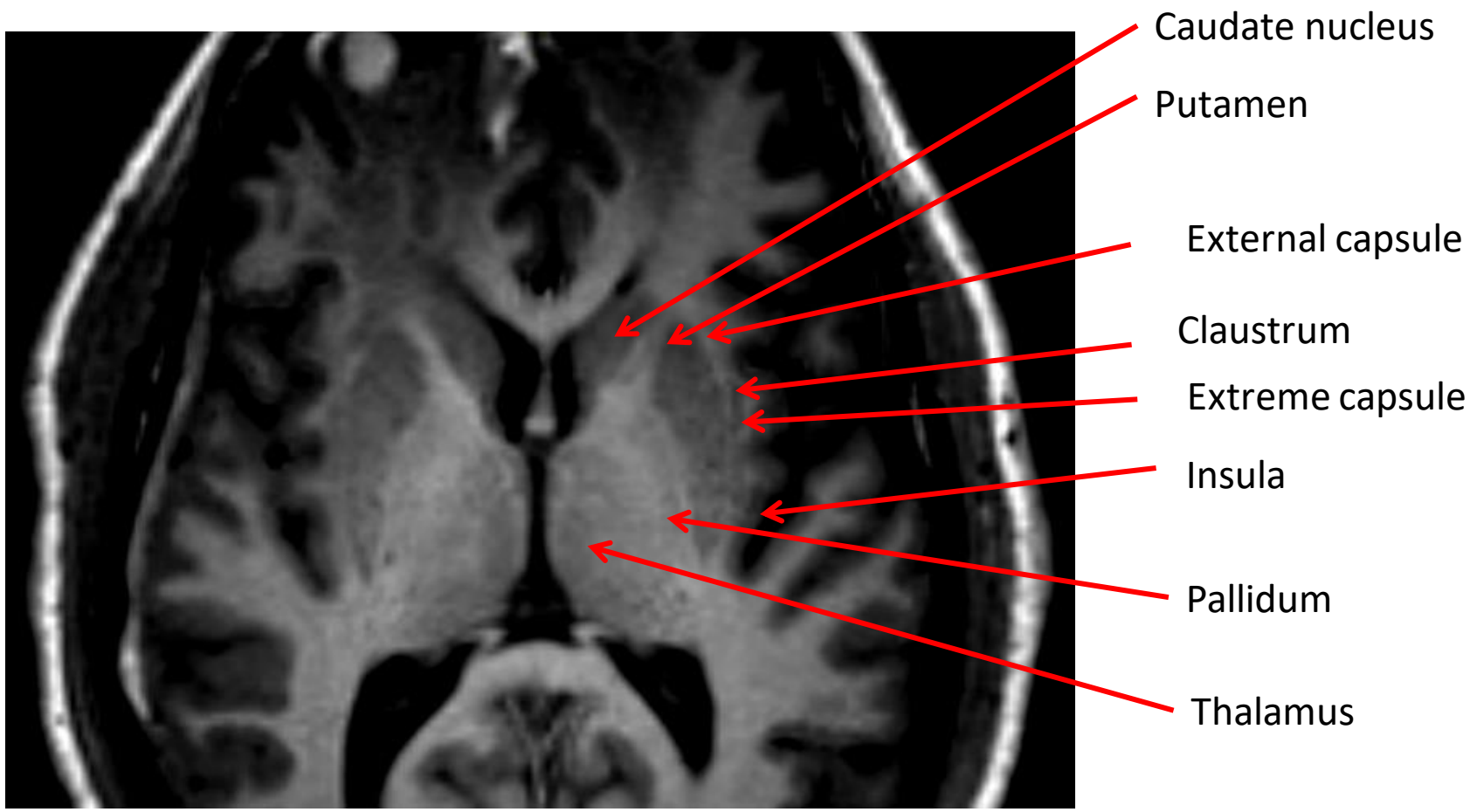

Hématome

J1

Hyperdensité

IRM en T1: hématome

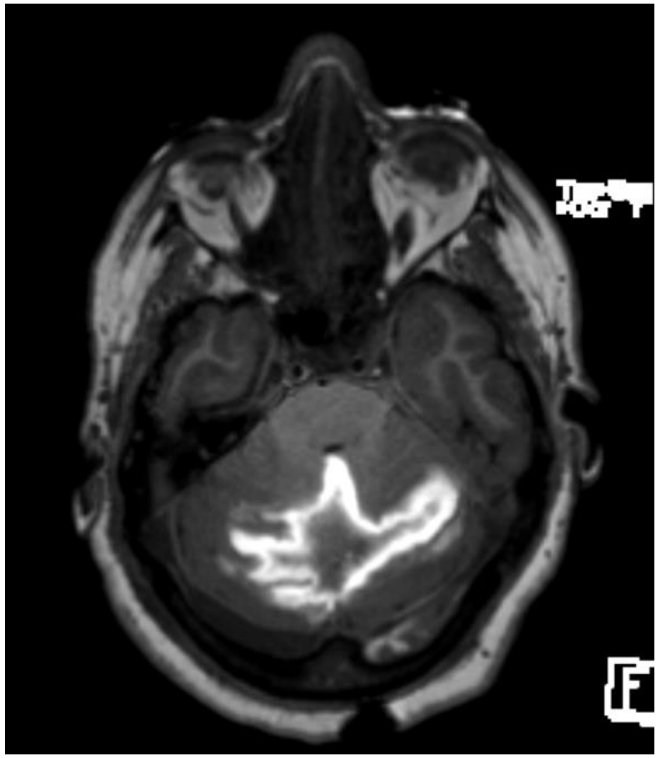

J10
Hématome sub-aigu
Hypersignal périphérique

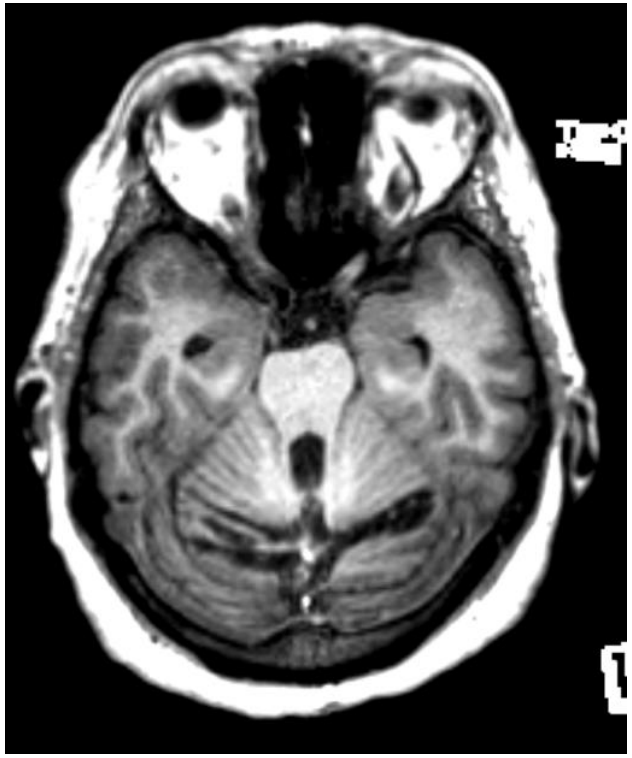

M4
Hématome chronique
Hyposignal (avec encore un peu d'hypersignal)

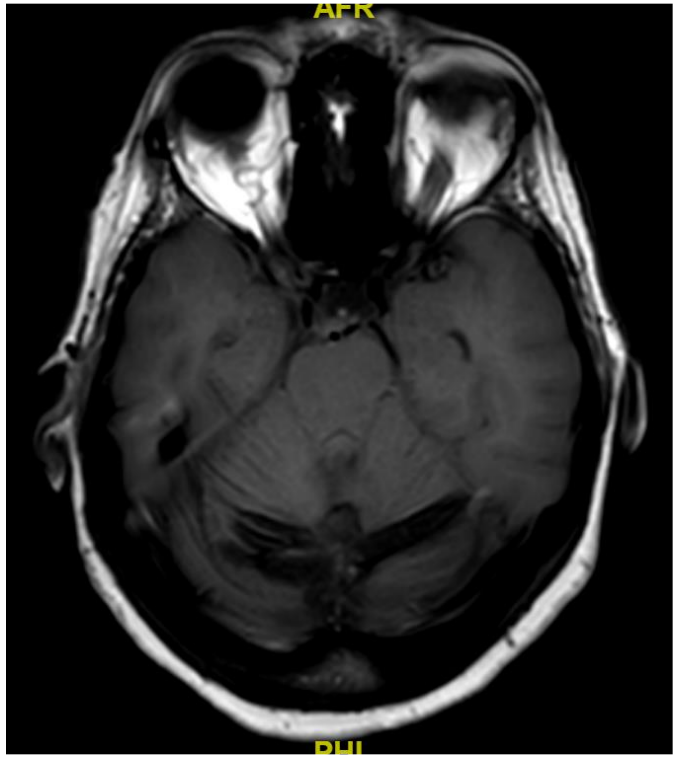

1 an
Hématome chronique
Hyposignal

IRM en T2*: hématome très récents et chroniques

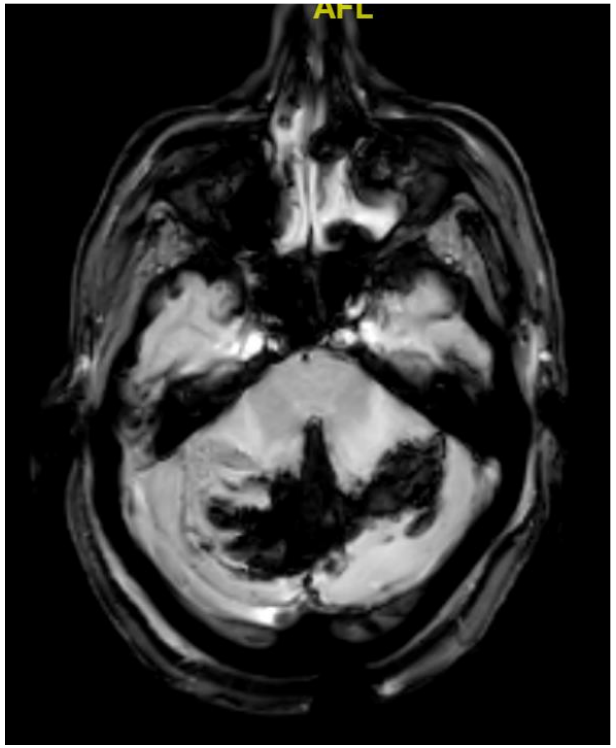

J4
Hématome aigu
hyposignal

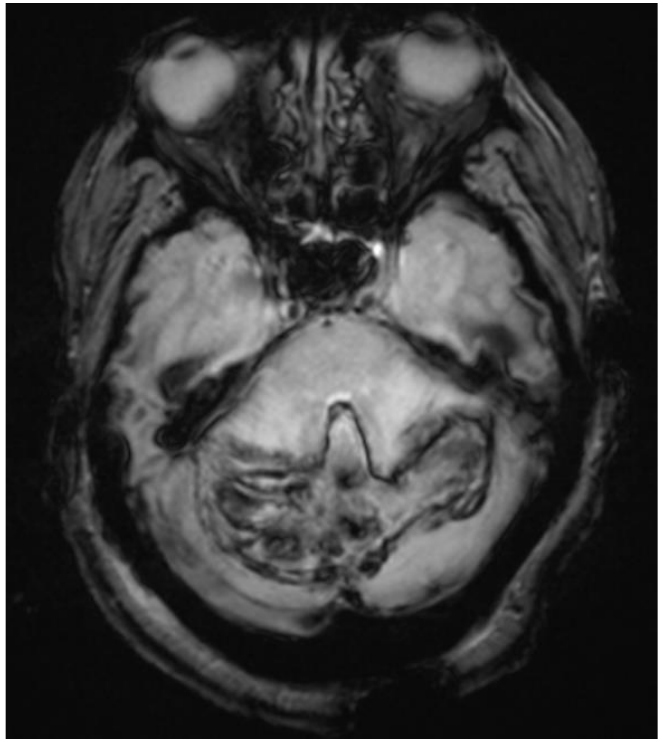

J10
Hématome sub-aigu
Hyposignal en couronne
(dehoxyHG)

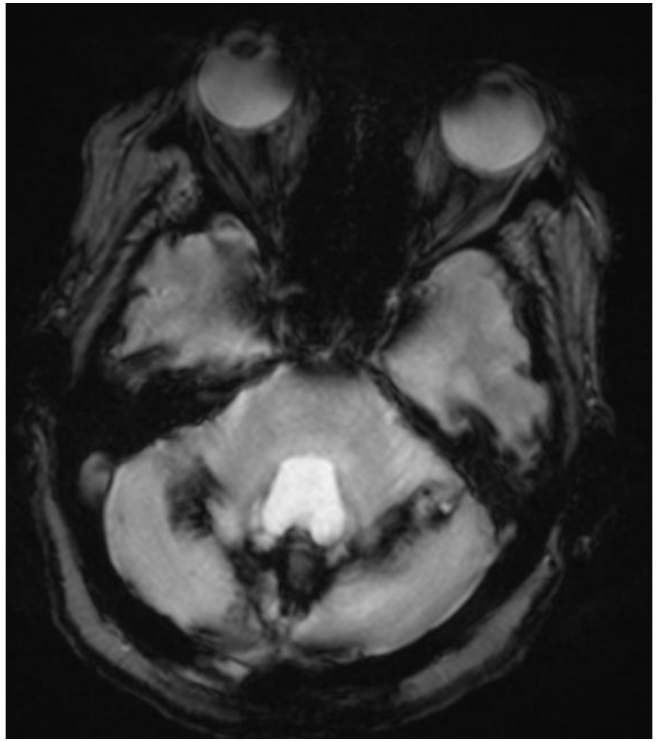

M4
Hyposignal
Hématome ancien
(hémosidérine)

IRM en T2 flair et hématome

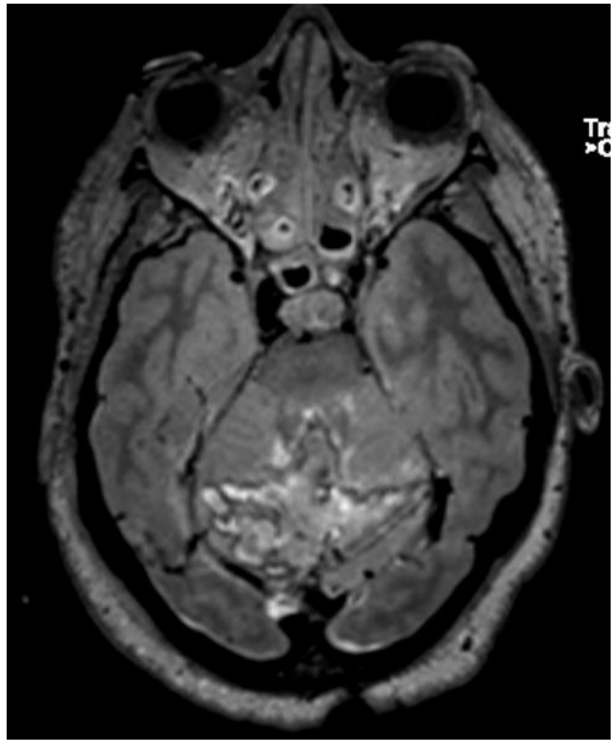

J10
Hématome sub-aigu
hypersignal

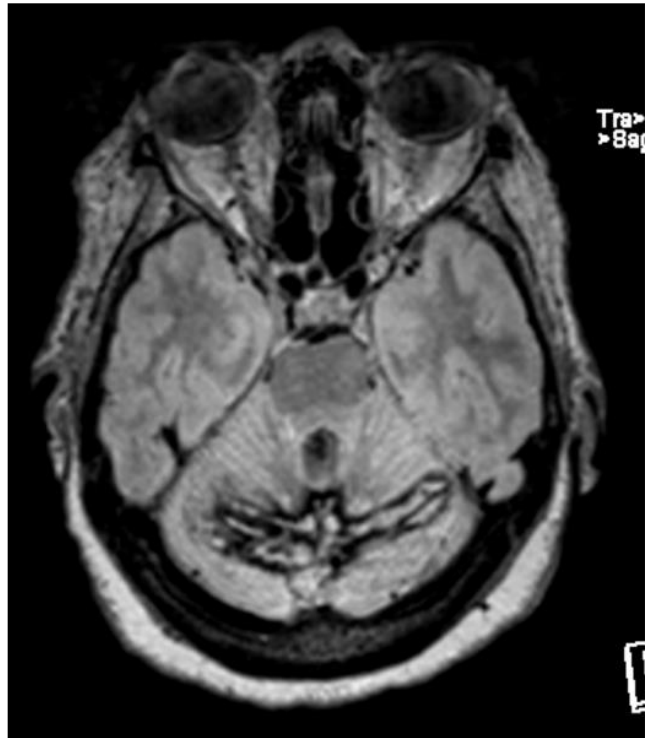

M4
Hématome ancien
Hyposignal hétérogène

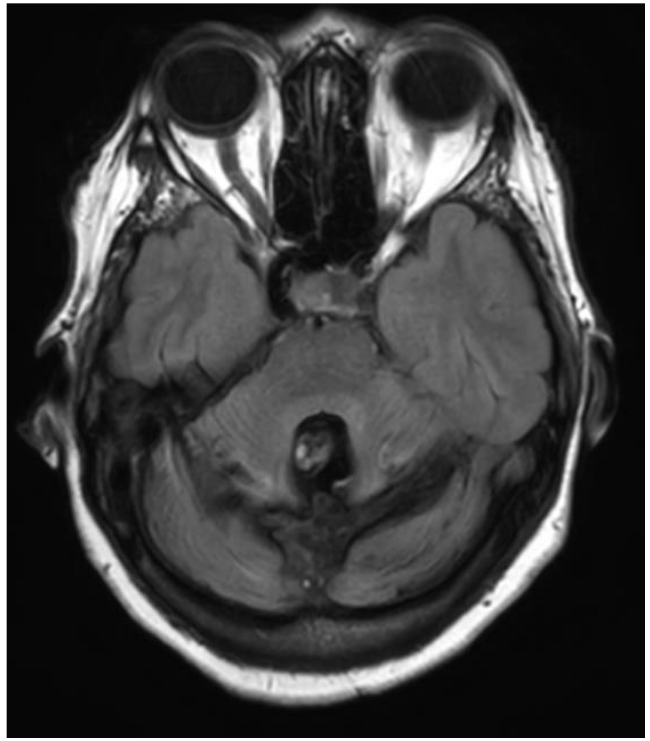

1 an
Hématome ancien
Hyposignal

Ischémie et séquences de diffusion

- L’objectif des séquences pondérées en diffusion est d’obtenir des images dont le contraste est influencé par les différences de mobilité des molécule d’eau.

- Chute de signal (hypo-signal) proportionnel au déplacement des molécules d’eau. En cas d’œdème cytotoxique (phase précoce de l’AVC), diminution importante du déplacement des molécules d’eau = hypersignal

Ischémie et séquences de diffusion

Signes précoces de l'ischémie : œdème cytotoxique (stade cellulaire réversible) : diminution de la mobilité des molécules d'eau après pondération B1000 = hypersignal

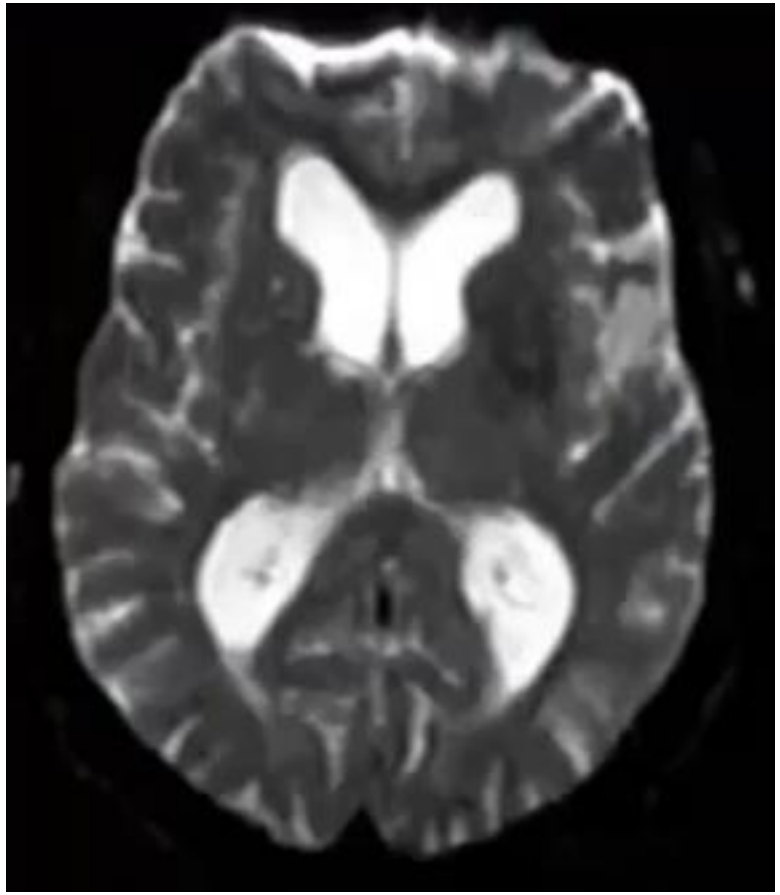

B=0

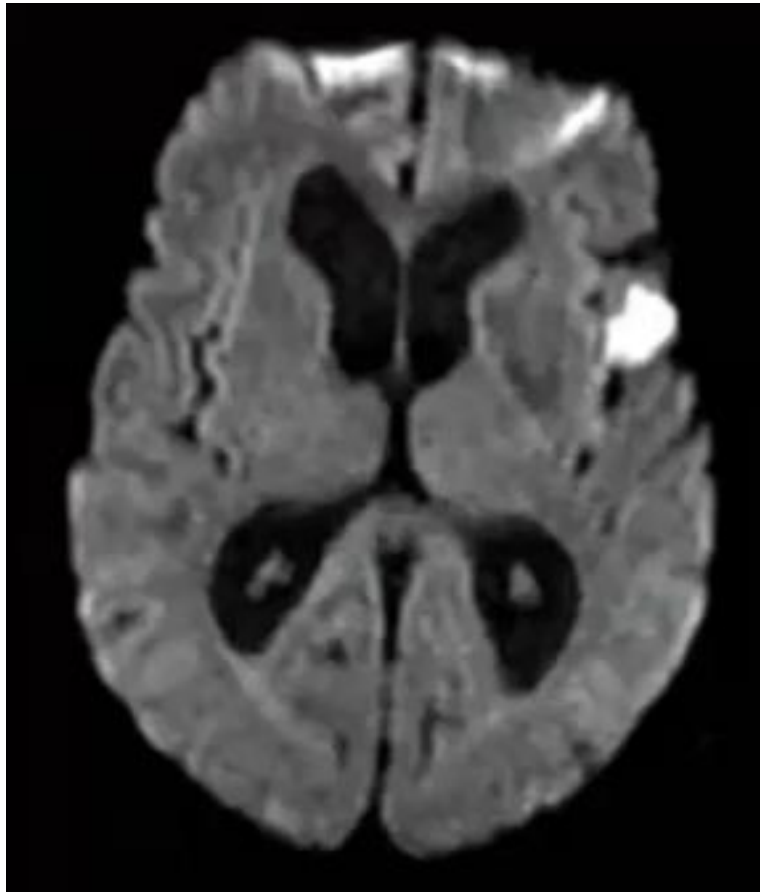

B=1000 s/mm2

Cartographie ADC

- Le degré de mobilité des molécules d'eau peut être évalué quantitativement en calculant le coefficient de diffusion apparent (ADC) : différence entre b = 0 s/mm2 (pondérée T_2) et b = 1000 s/mm2 (pondération en diffusion).
- L'ADC est représenté sous la forme d'une cartographie, dont les valeurs (en mm2s-1) ne dépendent plus du T_2, **un hyposignal correspondant alors à une restriction de la diffusion**.
- **La restriction de l'ADC est une des caractéristiques de l'ischémie précoce et du mismatch (hyposignal).**
- Puis œdème vasogénique : rupture des membranes ; l'œdème devient extra-celulaire : hypersignal en T2 (flair) = irréversibilité.

Signes précoces de l'ischémie : œdème cytotoxique (stade cellulaire réversible) : diminution de la mobilité des molécules d'eau après pondération B1000 = hypersignal ; cartographie ADC (b0-b100): hyposignal

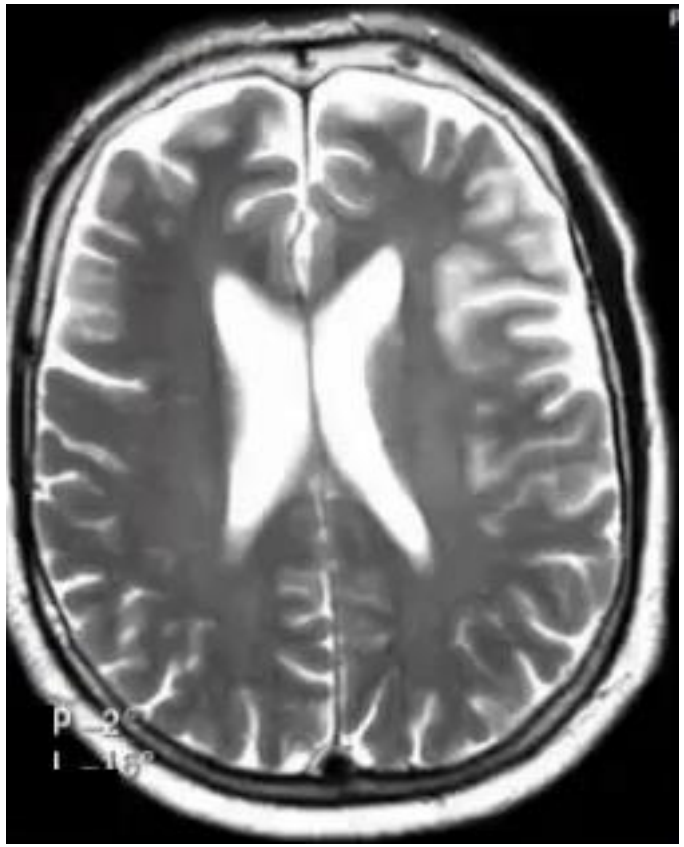

B=0

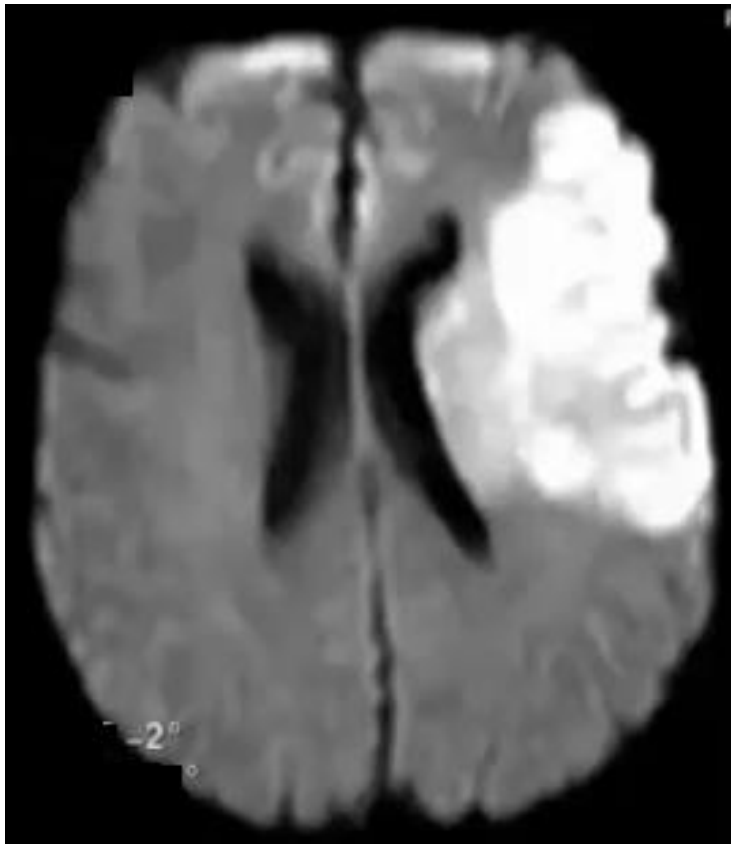

B=1000 s/mm2

ADC

Lésions anoxo-ischémique après ACR

- Diffusion: signes d’un œdème cytotoxique.
- Zones les plus exposées : noyaux gris, cortex : zones jonctionnelles (zones des derniers près) : cortex temporal interne (hippocampes), cortex pariétal postérieur ainsi que le cortex occipital et les hémisphères cérébelleux. Les images se « pseudo »normalisent à la fin de la première semaine.
- Les séquences T1 et T2 sont souvent normales. Les séquences T2 Flair peuvent montrer des signes (hypersignal) dans les jours qui suivent l’hypoxie-ischémie traduisant un œdème vasogénique qui peut régresser par la suite.
- Les lésions de type nécrose laminaire vont surtout entrainer une atrophie visible dans les semaines qui suivent l’hypoxie-anoxie.

Anoxie et IRM FLAIR réalisée 1 semaine après un ACR

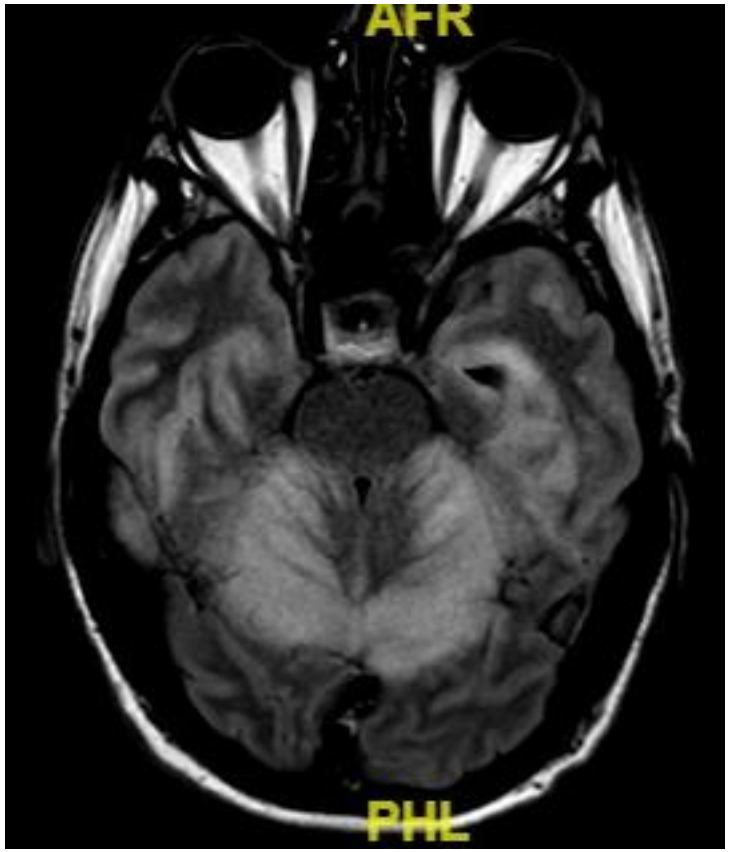

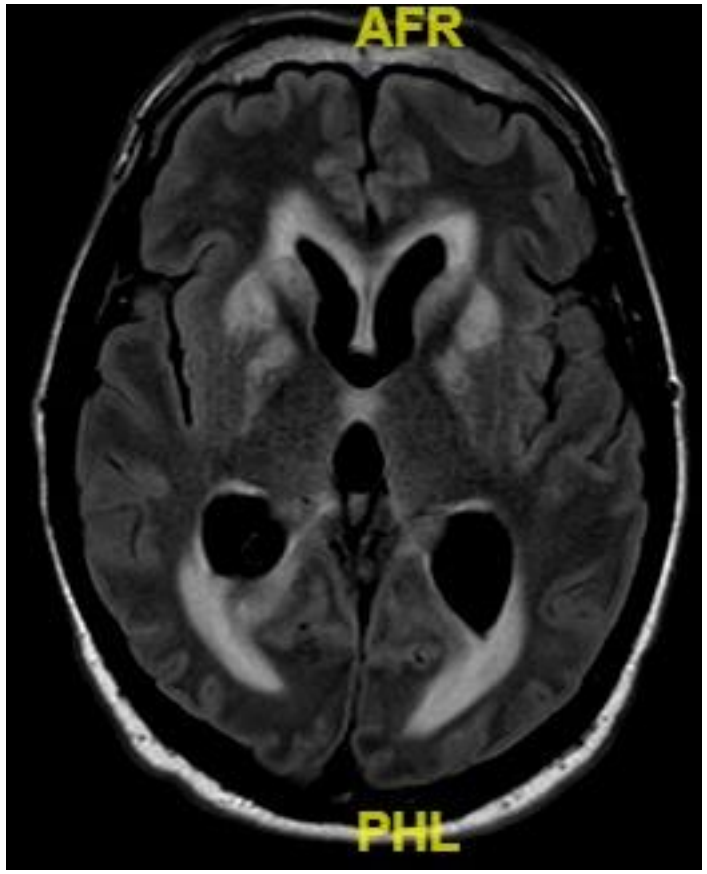

IRM T2 Flair à 2 mois d’une anoxie cérébrale par ACR

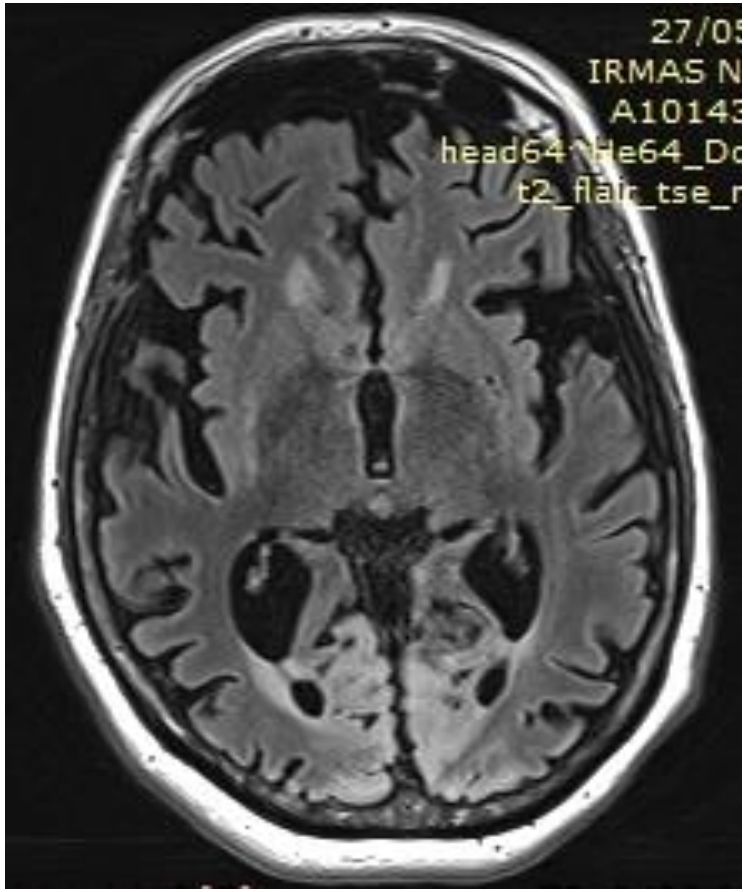

Lésions axonales diffuses hémorragiques

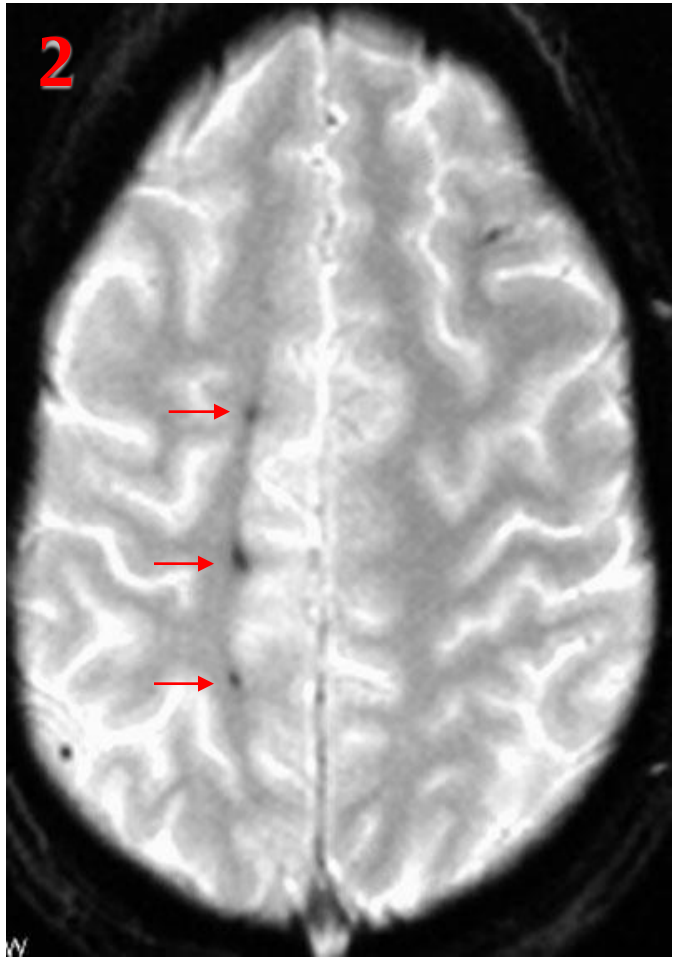

- T2 * : hyposignal

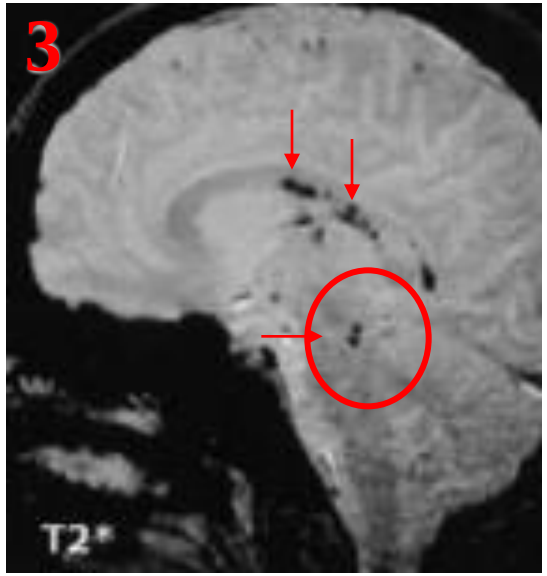

T2* vs SWI

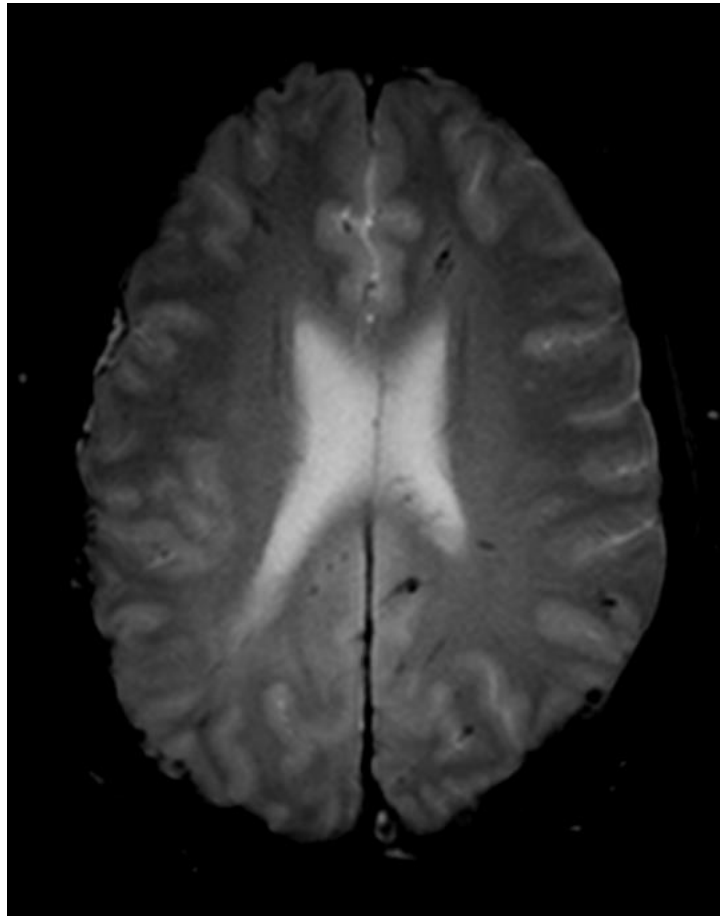

T2*

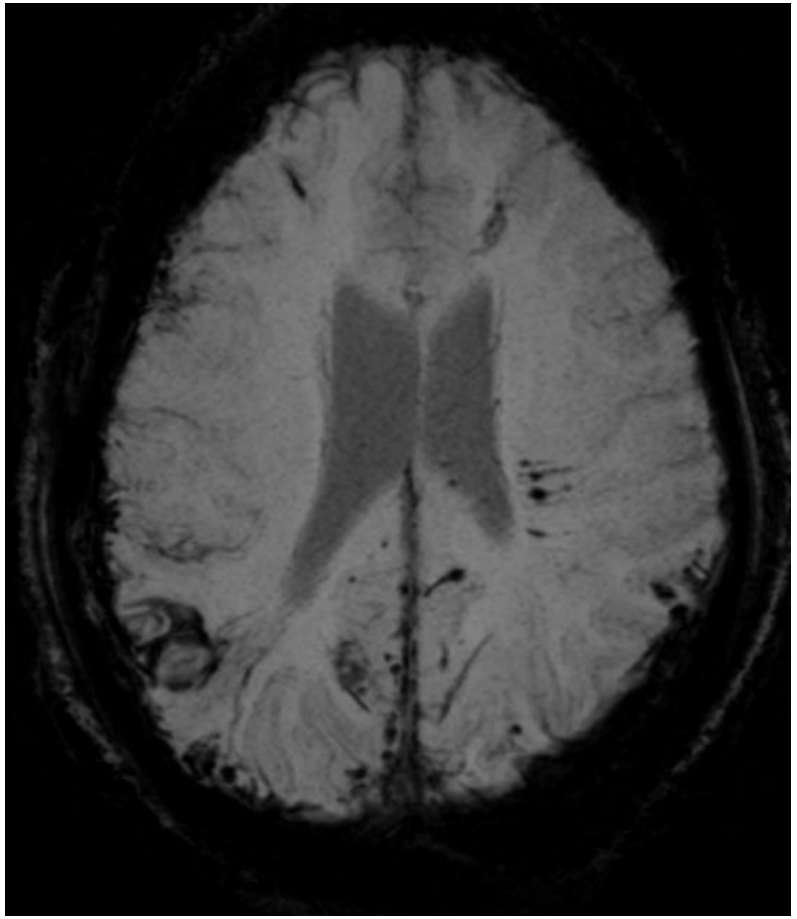

SWI